

ANATOMY,

DESCRIPTIVE AND SURGICAL.

BY

HENRY GRAY, F.R.S.,

FELLOW OF THE ROYAL COLLEGE OF SURGEONS; LECTURER ON ANATOMY AT ST. GEORGE'S
HOSPITAL MEDICAL SCHOOL.

EDITED BY

T. PICKERING PICK, F.R.C.S.,

CONSULTING SURGEON TO ST. GEORGE'S HOSPITAL AND TO THE VICTORIA HOSPITAL FOR CHILDREN;
H. M. INSPECTOR OF ANATOMY IN ENGLAND AND WALES,

AND

ROBERT HOWDEN, M.A., M.B., C.M.,


PROFESSOR OF ANATOMY IN THE UNIVERSITY OF DURHAM; EXAMINER IN ANATOMY IN
THE UNIVERSITIES OF DURHAM AND EDINBURGH, AND TO THE
BOARD OF EDUCATION, SOUTH KENSINGTON.

with a new Introduction by
JOHN A. CROCCO, M.D.

CHIEF OF PULMONARY SERVICES, ST. VINCENT'S HOSPITAL
AND MEDICAL CENTER OF NEW YORK,
AND ASSISTANT PROFESSOR OF CLINICAL MEDICINE,
NEW YORK UNIVERSITY SCHOOL OF MEDICINE

A REVISED AMERICAN. FROM THE FIFTEENTH ENGLISH, EDITION.

WITH 780 ILLUSTRATIONS, MANY OF WHICH ARE NEW.



The Class

**GRAY'S
ANATOMY**

780 illus

with a new In-
Chief of Pul-
Hospital and
and Assistan-
New York U-

This is
greatest te-
been an in-
its appeal
dents, but
As the ne-
"Ever
posed to
has used
pied mo-
hours,
cadaver
"Th
real co-
manu-
trated
been
mon-
How
"Th
ana-
and
ana-
con-

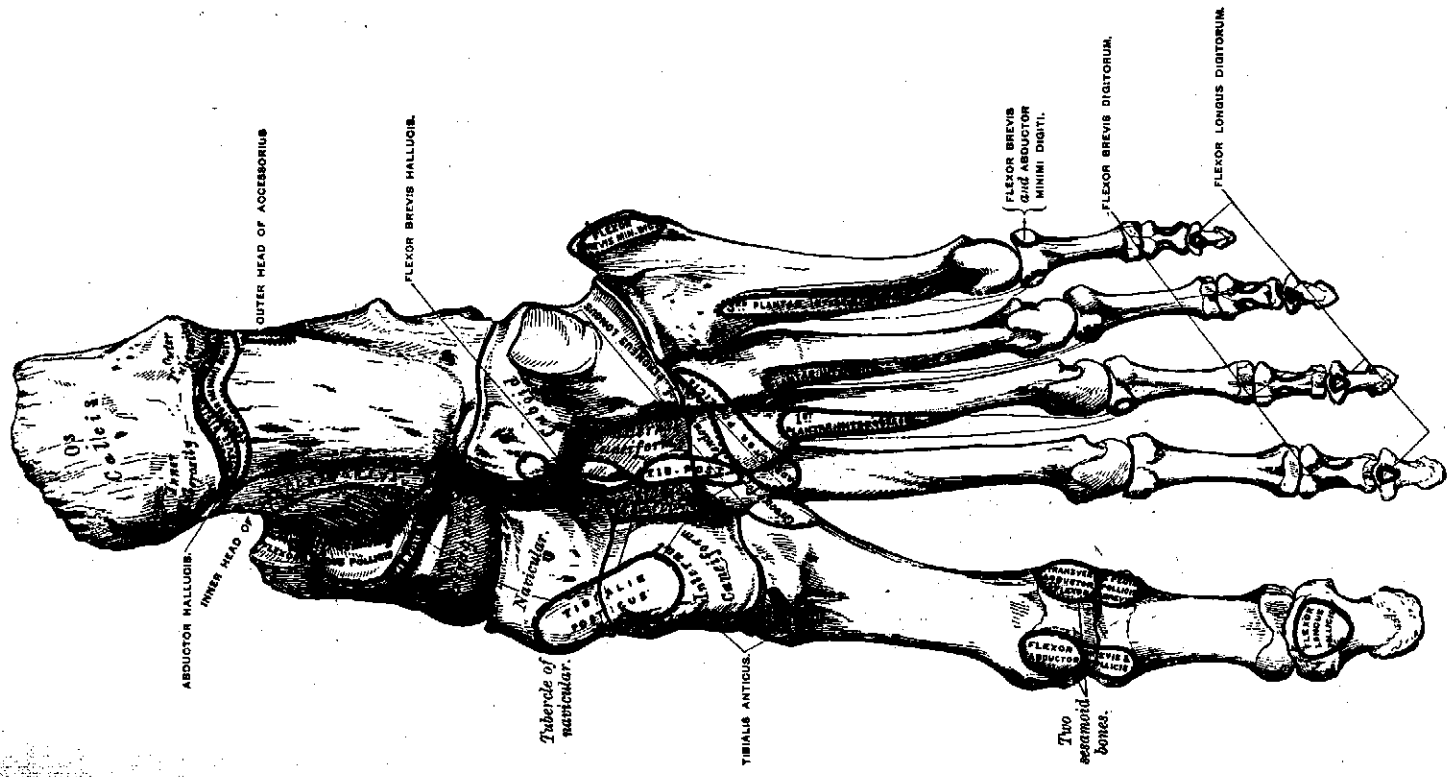
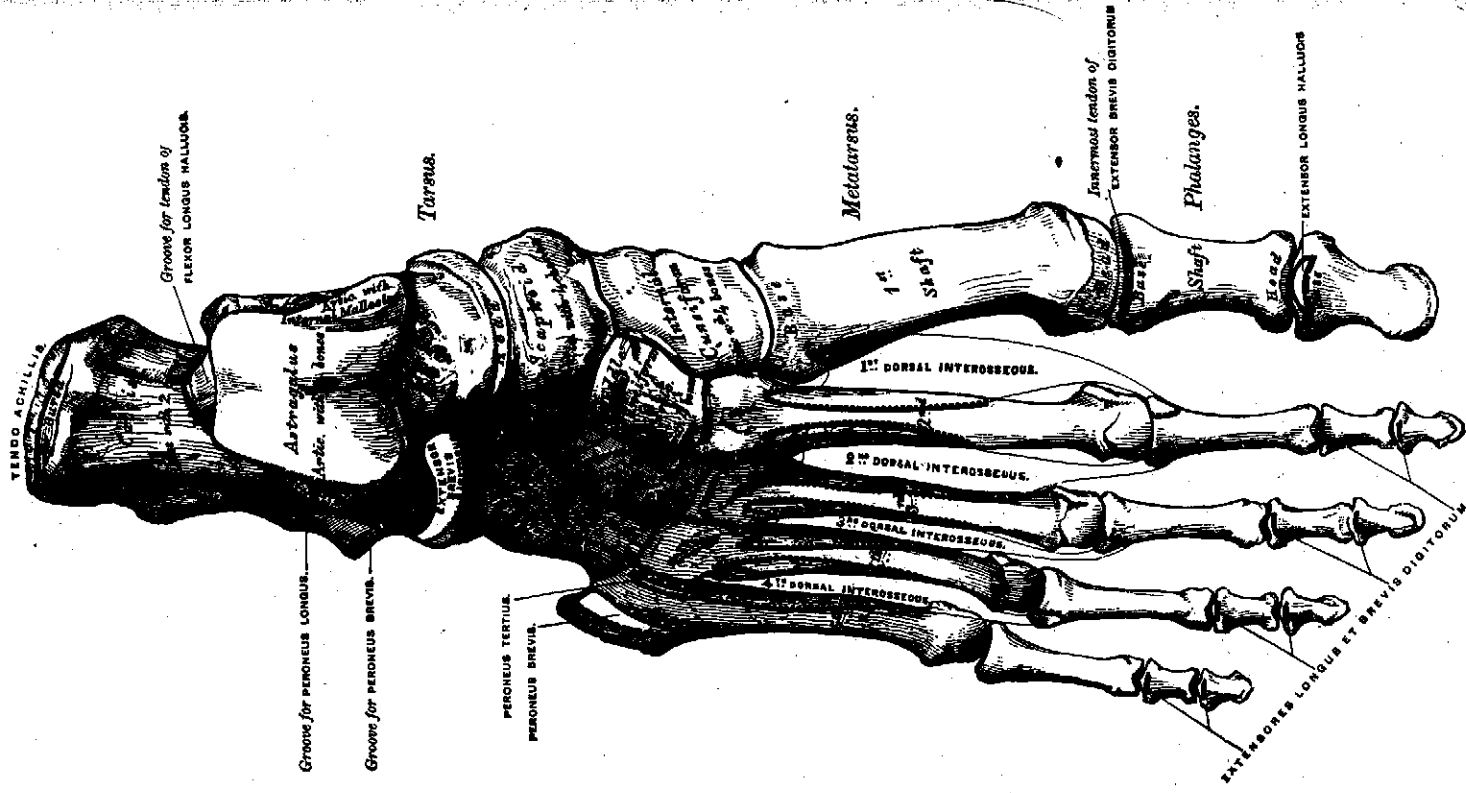


Fig. 188.—Bones of the right foot. Plantar surface.



CUNNINGHAM'S
TEXTBOOK OF
ANATOMY

ELEVENTH EDITION

EDITED BY

G. J. ROMANES, C.B.E.

B.A., PH.D., M.B., CH.B., F.R.C.S. ED., F.R.S.E.
Professor of Anatomy in the University of Edinburgh

LONDON

OXFORD UNIVERSITY PRESS

1972

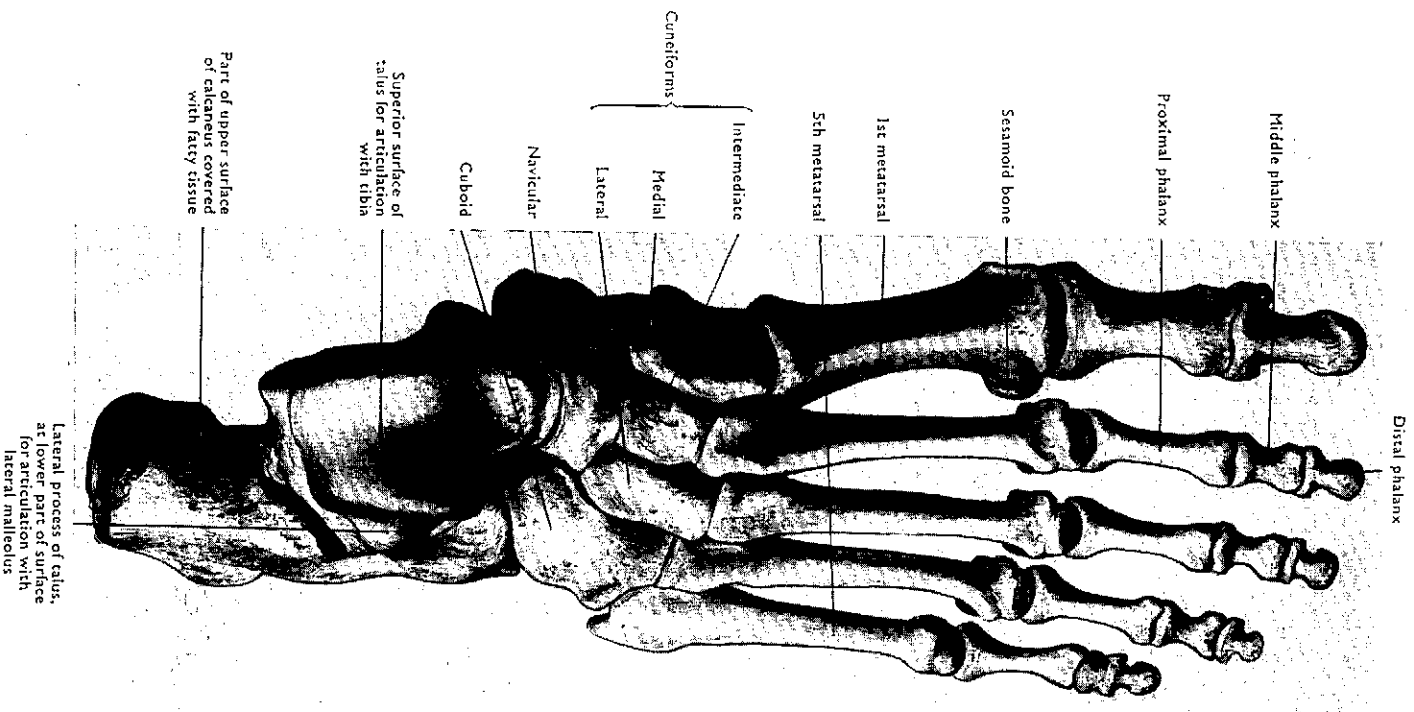


Fig. 248 Bones of right foot (superior or dorsal surface).

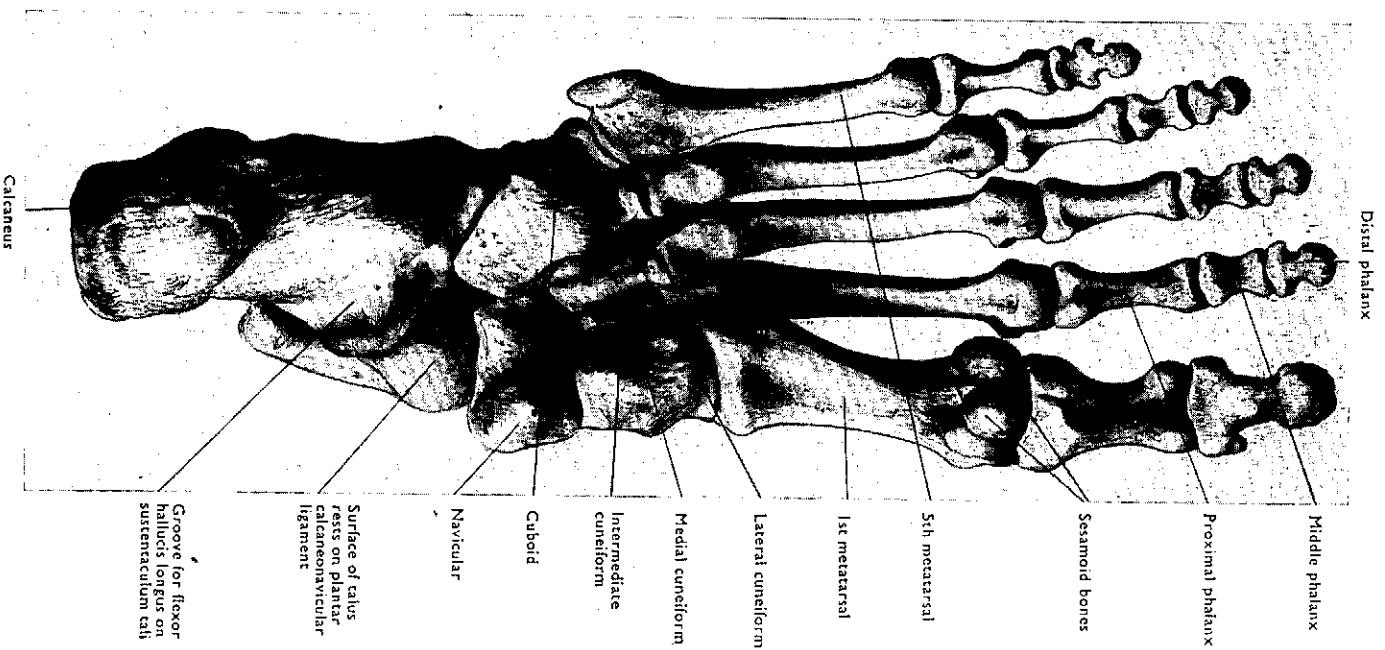


Fig. 249 Bones of right foot (inferior or plantar surface).