

# correlative neuroanatomy & functional neurology

**16th**  
EDITION

**JOSEPH G. CHUSID, MD**

Associate Clinical Professor of Neurology  
College of Physicians and Surgeons  
Columbia University (New York City)

Director of Department of Neurology  
St. Vincent's Hospital and Medical Center  
(New York City)

Associate Attending Neurologist  
Columbia-Presbyterian Medical Center  
(New York City)

Los Altos, California 94022

LANGE Medical Publications



Wrist drop in radial nerve injury

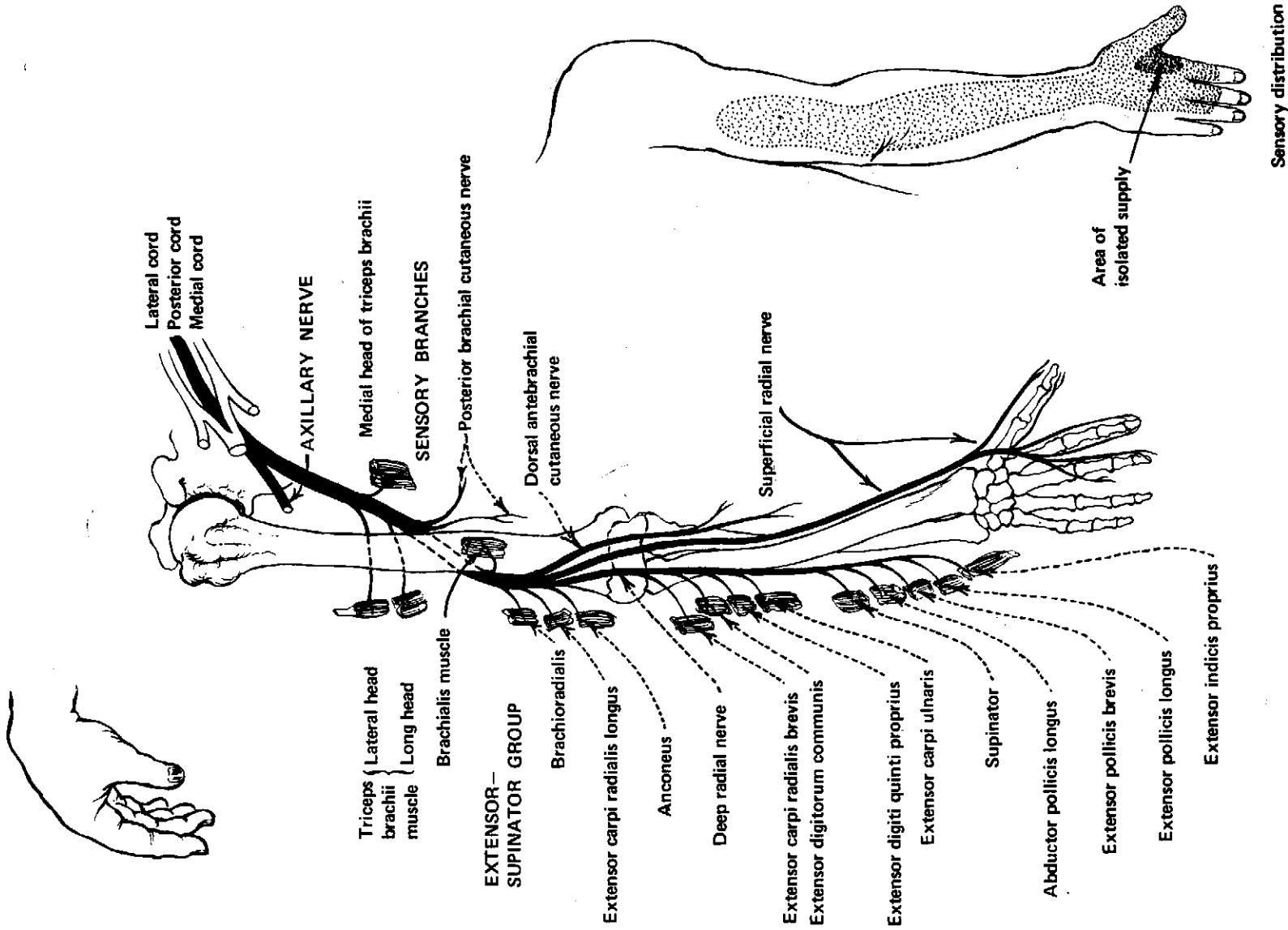


Figure 5-9. The radial (musculospiral) nerve (C6-8 and T1).

**THE RADIAL (MUSCULOSPIRAL) NERVE**

(C6-8 and T1)  
(See Fig 5-9.)

The radial nerve is the largest branch of the brachial plexus. It begins at the lower border of the pectoralis minor as the direct continuation of the posterior cord, and derives fibers from the last 3 cervical and first thoracic segments of the spinal cord. During its descent in the arm it accompanies the profunda artery behind and around the humerus and in the musculospiral groove. It pierces the lateral intermuscular septum and reaches the lower anterior side of the forearm, where its terminal branches arise.

Motor branches in the arm supply the triceps, anconeus, and the upper portion of the extensor-supinator group of forearm muscles. Motor branches in the forearm supplied by the deep radial nerve pass to the rest of the extensor-supinator group of muscles. Sensory branches supplying innervation to skin areas include the posterior brachial cutaneous nerve, to the dorsal aspect of the arm; the posterior antebrachial cutaneous nerve, to the dorsal surface of the forearm; and the superficial radial nerve, to the dorsal aspect of the radial half of the hand. The isolated area of supply is a small patch of skin over the dorsum of the first interosseous space.

**Lesions Affecting the Radial Nerve**

The radial nerve is the most commonly injured peripheral nerve. It may be involved in cervical cord and brachial plexus lesions. Peripheral injuries may affect the trunk or some of the branches of the nerve, as in dislocations of the shoulder, fractures of the humerus, callus formation around a fracture; pressure from a crutch or during sleep, anesthesia, drunkenness ("Saturday night palsy"), violent blows on the arm, tuberculosis of the bone, tumors, syphilis (rare), or fractures of the neck of the radius. Toxic (alcohol, lead, arsenic) or infectious neuritis and polyneuritis involving the radial nerve also occur.

**Clinical Features of Peripheral Radial Nerve Lesions**

**A. Motor Signs of Complete Radial Nerve Palsy:** Extensor paralysis: inability to extend the thumb, proximal phalanges, wrist, and elbow; pronation of the hand, with the wrist and fingers flexed in a position termed "wrist drop"; adduction of the thumb, which may interfere with flexion of the index finger; and inability to grasp objects adequately or to make a fist because of the wrist drop interferes with the action of the flexors. Triceps, radial, and periotarso-radial reflexes absent. (Supplementary movements may partially mask a radial palsy; energetic contraction of finger flexors and occasionally the pronator teres may extend the wrist.)

**B. Sensory Disturbances:** Sensory loss is slight (due to overlap), being most marked on the dorsal radial surface of the hand. Pain is rare.

**C. Vasomotor and Secretory Disturbances:** These are absent or very slight.

**D. Muscle Atrophy:** Muscle atrophy develops in 2-3 months and may be very marked on the dorsum of the forearm. Palsies due to pressure do not show atrophy.

**E. Radial Nerve Lesions Which Occur:**

1. Below the triceps innervation—Power to extend elbow retained.
2. Below the brachioradialis branch—Retain some supination ability.
3. In the forearm—May affect branches to small muscle groups: extensors of the thumb, extensors of the index finger, extensors of the fingers and extensor carpi ulnaris.
4. On the dorsum of the wrist—Show only sensory loss on the hand.

**F. Partial Lesions:** Partial lesions of the radial nerve in the arm occasionally affect fascicles to small muscle groups like those cited above.

**THE MEDIAN NERVE**

(C6-8, T1)  
(See Fig 5-10.)

The median nerve arises from the brachial plexus by 2 heads: a medial head from the medial cord and a lateral head from the lateral cord. The 2 heads unite at the lower margin of the pectoralis minor muscle. The trunk thus derives its fibers from the lower 3 (sometimes 4) cervical and the first thoracic segments of the spinal cord. In the arm it has no branches; the trunk descends along the course of the brachial artery and passes onto the volar side of the forearm, where it gives off muscular branches, and enters the hand where it terminates with muscular and cutaneous branches. Motor branches pass to most of the flexor-pronator muscles of the forearm, supplying all of the superficial volar muscles except the flexor carpi ulnaris, and all of the deep volar muscles except the ulnar half of the flexor digitorum profundus. In the hand they supply the first 2 lumbricals and the thenar muscles which lie superficial to the tendon of the flexor pollicis longus. Sensory branches supply the skin of the palmar aspect of the thumb and the lateral 2½ fingers, and the distal ends of the same fingers. Many vasomotor and trophic fibers are also distributed by the median nerve.

**Lesions.** Cervical cord and brachial plexus lesions may involve the median nerve. Peripheral nerve injuries may occur in lacerations of the arm, forearm, wrist, or hand due to automobile accidents, stab wounds, bullets, broken water faucets, suicidal attempts, etc.; due to prolonged compression in sleep, anesthesia, or rarely, by cervical rib; or due to dislocations of the ulna or fractures of the elbow joint and lower radius. Toxic or infectious neuritis or polyneuritis involving the median nerve also occurs.

**Clinical Features of Peripheral Median Nerve Lesions**

**A. Motor Signs (of Complete Lesions):** Paralysis of the flexor-pronator and thenar muscles. In the fore-