

Modern Manual Therapy of the Vertebral Column

Edited by

Gregory P. Grieve FCSP DipTP

Formerly Clinical Tutor, Royal National Orthopaedic Hospital, London,
and Norfolk and Norwich Hospital, Norwich, United Kingdom



CHURCHILL LIVINGSTONE

EDINBURGH LONDON MELBOURNE AND NEW YORK 1986

Examination of the thoracic spine

When studies of the pathology of vertebral disorders gathered pace early in the century, much attention was focused on the cervical and lumbar regions. This is understandable since the majority of overt joint problems seem to occur in these areas. However, one notes how often chest and abdominal pains were, and still are, diagnosed as symptoms of visceral disorders when in fact they have been the direct result of referral from the thoracic spine. It is an area which has been sadly neglected over the years and more research is long overdue (see Ch. 37).

One of the reasons for the lack of research in this area may be that the thorax is generally considered as being a relatively motionless and rigid structure, contributing little to overall spinal motion. Certainly, thoracic movement is limited, but it is of a particularly interesting nature when studied. The small gliding movements of the ribs which have the effect of producing large increases in all diameters of the thorax, and the coupling motions occurring in the thoracic spine, provide but two examples of the intricacy of such movements and the ability of the thorax to take full advantage of its limitations.

This chapter describes the physical examination of the thoracic spine and rib cage. However, before one can understand and interpret the significance of symptoms, it is essential to be familiar with the common sources of thoracic pain.

Thoracic joints and dura mater

The thoracic spine has more articulations than any other spinal region. In addition to the intervertebral body and apophysal joints, it has two extra joint complexes in the form of the costovertebral and costotransverse joints. It is not surprising that a lesion of one or more of these joints may produce pain in the posterior thorax either centrally or unilaterally. When anterior chest pain is present, the possibility of sternocostal joint and costochondral junction lesions contributing to the symptoms should not be forgotten.

Although it is relatively uncommon to find frank disc

lesions in the thoracic spine, this possibility must not be forgotten. Compression of an intercostal nerve root will produce pain which initially is felt posteriorly and then radiates anteriorly. Occasionally the patient will complain only of abdominal or sternal pain. In the presence of a larger protrusion, usually below the T6 level, the patient may complain of paraesthesiae below the level of the lesion and a feeling of tightness around the chest and abdomen as well as numbness of the trunk or legs. Carson et al (1971) noted, in a study of the diagnosis and treatment of thoracic intervertebral disc protrusions, that one in three of the patients complained of cold feet. He also observed that every patient showed some weakness of the legs. Similarly, when the upper half of the thoracic region is involved, pain in the posterior and medial aspects of the upper arm and the axillary region may be more predominant than the thoracic pain. This is due to the fact that the 1st thoracic nerve joins the brachial plexus and the lateral cutaneous branches of the 2nd, 3rd and sometimes 4th thoracic nerves supply this area, either directly or via filaments to the medial cutaneous nerve of the arm and the posterior brachial cutaneous branch of the radial nerve (Gray, 1973). It is also interesting to note that the lateral branch of the dorsal rami of T2 does not emerge superficially until it reaches T6 level and then ascends up to the acromion. The sympathetic supply to the upper limb receives fibres from as low as T8. Thus the possibility of symptoms in the upper limb arising from as low as this level cannot be excluded.

Symptoms may arise as a result of irritation of any of the pain sensitive structures within the joint complex. For example, in ankylosing spondylitis, pain in the inter-scapular and sternal areas is thought to be of ligamentous origin (Cyriax, 1975).³ Similarly, kyphotic compression of the anterior aspects of vertebral bodies following wedge fractures and the resultant soft tissue stretch in the posterior structures may produce a post-central ache. Mooney & Robertson (1976)⁴ noted that an injection of saline into the apophysal joints was sufficient to produce referred pain similar to that normally diagnosed as being

they can be misleading. Adson's Test (Chusid, 1973)⁹ shows that the radial pulse can be obliterated if the patient sits with his hands on his thighs, inspires deeply and holds his breath while extending the head and rotating it to one side and then the other. If obliteration of the pulse on the affected side occurs, the test is said to be positive. However, a positive result can occur in asymptomatic individuals. The syndrome often occurs as a result of trespass or irritation by bony and/or connective tissue anomalies. The presence of a cervical rib is said to be responsible for the irritation of the brachial plexus. However, many individuals have cervical ribs but do not have symptoms. Scalenus anterior and medius are separated by only the subclavian artery and brachial plexus. Thus any connective tissue proliferations in this region are likely to produce the above symptoms.

The heart

Patients presenting with left-sided anterior chest pain are often initially diagnosed as having angina pectoris and referred for further investigation.¹⁰ However, results of tests are often negative and thus other sources must be considered. Lindahl & Hamberg (1981)¹¹ state that pathological changes in the oesophagus, mediastinum and thoracic spine can produce chest pain which is identical to that of angina. They also mention experimental evidence to show that actual penetration of the heart wall is painless but pinching or pressing of the pericardium elicits pain. The authors mention that the sympathetic nerves to the heart are derived from segments C3-T6 and stimulation of these can result in pain experienced in the root of the neck, upper limb and hand, as well as the anterior chest. It therefore becomes exceedingly difficult to decide which of the above possible causes is responsible for the symptoms, particularly so when the patient has a previous history of coronary artery disease. However, if the pain is aggravated by deep breathing, coughing, and/or thoracic posture on movement, the possibility of the heart being the only mechanism responsible for the symptoms is unlikely.

Diaphragm, pleura and lung, viscera

The diaphragm is situated in close proximity to the abdominal organs whose nerve supply often communicates with that of this major respiratory muscle. The phrenic nerve, which is the sole motor nerve supply to the diaphragm, is mainly derived from the 4th cervical nerve, with contributions from the 3rd and 5th. On reaching the inferior surface of the diaphragm, it communicates with branches of the coeliac plexus which is responsible for the innervation of the suprarenal glands, the liver, inferior vena cava and gall-bladder (Gray, 1973).² Thus it is possible for a malfunction in one of these organs to refer pain along the C4 and adjacent dermatome to the shoulder

movements. Several tests exist to confirm the diagnosis but in the hand and inability to perform well coordinated movements. Several tests exist to confirm the diagnosis but wasting in the group supplied by T1, occasional weakness and of the C8 and/or T1 nerve root, muscle weakness and patient presents with paraesthesiae along the distribution hand as well as a bluish discoloration. Neurologically, the pain, puffiness, swelling, and heaviness of the arm and ones to note are the diminished radial and ulnar pulses, vascular features occurring, perhaps the most important of brachial plexus in the thoracic outlet. Of the many direct pressure on the subclavian vessels and/or lower trunk (Grieve, 1981).⁸ These occur as a result of irritation or invariably showing a predominance over the neurological neurological features in the arm and hand, the vascular Pancoast's tumour. He complains of both vascular and dylosis, carpal tunnel syndrome or, less commonly, is often diagnosed, for example, as having cervical spondylosis, carpal tunnel syndrome or, less commonly, with symptoms typical of the thoracic outlet syndrome, he It is appropriate to mention that if a patient presents symptoms suggest a lesion of thoracic spinal origin. necessary to include examination of the neck even when the lower three cervical segments (Cloward, 1959).⁷ Thus it is thoracic region from outside its confines, i.e. from the Similarly, pain is commonly referred into the upper joints can refer pain to areas totally outside the thorax. So far we have briefly observed how lesions of the thoracic

The neck

In a further study in 1968, Nathan⁵ explored the possibility of compression of the sympathetic trunk by osteophytes of the vertebral column in the abdomen. He found that 78.4% of the cadavers studied showed the presence of osteophytes compressing the sympathetic trunks. If such a similar situation could arise in the thoracic spine, possibly underlying complaints of temperature changes in the lower limbs or affected thoracic area, dryness of skin of the trunk and/or limbs and paraesthesiae.

producing narrowing of the intervertebral foramina. In a further study in 1968, Nathan⁵ explored the possibility of compression of the sympathetic trunk by osteophytes of the vertebral column in the abdomen. He found that 78.4% of the cadavers studied showed the presence of osteophytes compressing the sympathetic trunks. If such a similar situation could arise in the thoracic spine, possibly underlying complaints of temperature changes in the lower limbs or affected thoracic area, dryness of skin of the trunk and/or limbs and paraesthesiae.

vidual dorsal rami evoked reflex activity in the hamstrings. This reflex was polysynaptic and was mediated by the smaller diameter fibres on the dorsal rami. Not all motor units in the hamstrings were activated by a given stimulus. While some units responded others, as near as 1 cm away, remained silent. Some units, initially inactive, responded to sustained or more intense stimulation of the back. The reflex activity was unilateral or bilateral, but was detected only in those muscles innervated by the same spinal cord segments from which the stimulated dorsal rami were derived. Similar observations in cats have been reported following the stimulation of the articular branches to the lumbar zygapophysal joints²⁰.

Comparable phenomena have been observed in man.

Bogduk & Munro^{9,26} found that injections of hypertonic saline into the L5 interspinous ligament or into the multifidus muscle produced electromyographically detectable activity in the multifidus, gluteus medius and tensor fasciae latae muscles. This activity followed the onset of back pain, lasted only as long as the back pain, and occurred regardless of whether referred pain occurred or not. Mooney & Robertson¹¹ found that, in normal volunteers, injections of hypertonic saline into the L4-5 or L5-S1 zygapophysal joints produced electromyographic activity in the hamstrings, and caused a limitation of straight leg raising. Anaesthesia of the stimulated joints obliterated the increased muscle activity. In six patients presenting with limitation of straight leg raising, Mooney & Robertson¹¹ were able to restore normal straight leg raising, by anaesthetizing zygapophysal joints, revealing that the cause of limitation was spasm of the hamstrings secondary to zygapophysal joint pain.

PATHOLOGY

The potential causes of lumbar dorsal ramus syndromes can be established by systematically reviewing the pathology of the several structures innervated by the lumbar dorsal rami.

Ligaments

The interspinous ligaments can be affected by a variety of degenerative changes³¹, but there is no evidence that these changes are painful. The only established painful condition of the interspinous space is Bastrup's disease, or 'kissing spines'³²⁻³⁴. In this condition, subluxation of a vertebra results in approximation of adjacent spinous processes, especially on extension, and the formation of a painful pseudoarthrosis. Clinically Bastrup's disease poses no diagnostic problem. Focal tenderness over an interspinous space raises suspicion, and the radiological appearance of the condition is diagnostic.

Otherwise, the interspinous ligaments have been shown

Muscle pain

Theoretically, disorders of the lumbar back muscles are possible causes of lumbar dorsal ramus syndrome, but little is known of the pathology of painful muscle disorders. Acute strains or tears of the back muscles are clinically recognized causes of pain, but because these conditions usually resolve spontaneously they have not attracted pathological study. No scientific comment, therefore, can be made as to how, and if, acute muscle trauma proceeds to cause persistent or chronic back pain.

Painful spasm of the back muscles is another clinically recognized phenomenon. As described above, muscle spasm is a reflex response to noxious stimulation of dorsal rami, but if, and how, pain is produced in this state is unknown. A possible hypothesis is that continuous activity in some, or all, motor units in a muscle imparts the circulation of blood through those active units, enabling the accumulation of noxious metabolites such as lactic acid or adenosine diphosphate.

Trigger points may occur in the back muscles, causing local pain, referred pain, muscle spasm, and secondary trigger points in the lower limb, all of which can be relieved, at least temporarily, by infiltrating the primary trigger point with local anaesthetic^{14-18,43-45}. The pathology of trigger points remains enigmatic. The results of histological studies have been equivocal^{46,47}, but physiological studies indicate that trigger points represent areas of hyper-

Lumbar fat herniation

Herniation of fat through the thoracolumbar fascia was first described by Copeman & Ackerman^{35,36}, and has been reiterated as a cause of low back pain and referred pain by several others³⁷⁻⁴². This condition is characterized by the finding of a mobile tender nodule along the lateral border of erector spinae. Infiltration of the nodule with local anaesthetic, or its excision, relieves all symptoms. Histologically, the nodules are found to be normal fat and not lipomata. The pain in this condition is probably produced by the hernia stretching the thoracolumbar fascia or surrounding connective tissue.

The abandoned headache syndrome

J. Edeling

Chronic headaches which are of cervical articular origin respond well to and can be brought under control by localized mobilization of the affected joints. But this, the treatment of choice, is rarely available to such sufferers for reasons to be set out.

The Abandoned Headache Syndrome is the name suggested for this condition by the author. It is shown to be an unrecognized cervical headache, only diagnosed in retrospect when it has responded to mobilization of the upper cervical spine, having been unresponsive to all previous treatments which were appropriate to other diagnoses.

A TYPICAL HISTORY

On first becoming interested in headaches I encouraged patients to tell me just how they felt, and was struck by their accounts of unabated suffering. The history would have begun a long time before first contact with the patient, and would have unfolded roughly as follows:

For many years *she* ('*she*' refers throughout to the patient) would have experienced a 'normal' headache, by which she meant an occasional headache of mild to moderate intensity and which was totally relieved by a simple analgesic. Then, over the years, the symptoms gathered momentum. The headaches became more frequent as well as more severe and at a certain stage became continuous. By this time the pain fluctuated from mild to moderate to quite alarming levels. As the clinical history progressed, it emerged that the headaches could be accompanied by any combination of a multitude of bizarre symptoms which often frightened the patient. Nausea and vomiting made her feel wretched enough, but when she began to see flashing lights and to hear strange sounds, feeling all the while that her head might burst, she began to doubt her sanity. The dominant symptom was pain, often of disabling intensity. Relentless escalation of the symptoms had progressed

At the 'normal headache' stage the patient did not seek help. She knew that under certain circumstances she would have a headache and supposed that everyone else would have too. When she realized that the headaches were becoming more frequent and more severe and that her usual headache pills were less effective she sought medical help, confident that her doctor would diagnose the trouble and cure it. She became confused when he mentioned various possibilities such as migraine or tension, and when the expensive and potent drugs that he prescribed did not halt the progression of symptoms she became anxious and demanded specialist opinion. The line of referral often started at the eye specialist because reading or close work seemed to aggravate the pain. Next, she may have been sent to an ENT specialist in case congested nasal sinuses were the cause. If the headaches were related to her menstrual period she would see a gynaecologist. Physicians would check her blood pressure and seek other systemic disorders. Any positive findings were corrected or treated in the hope of relieving the headache.

Should these measures all have failed, and the headaches had by that time become of increasing severity, with a complexity of associated symptoms, she would enter a morbid fears, most commonly cancer of the brain.

When neurological tests excluded this possibility, her comfort was shortlived. The neurologist told her that there was no physiological basis for her headache. By that he meant that nothing was pressing on her brain. He mistakenly thought that this information would relieve her of anxiety, but he had only replaced one fear with another. The layman interprets this disclosure as 'there is nothing physically wrong with you' and deduces 'You can't really have a headache; you just think, or

way. These proven cases will be referred to in the text as 'the sample', which will distinguish the true cervical headache from the cervical headache syndrome taken from the literature.

Comparative study

This study was begun in 1971. Two years later, results were analysed and reported.²

Cases treated: 105
Of these, 95 responded with prompt relief of pain and other symptoms

10 did not respond favourably or at all.
The cases were followed up 6 to 12 months later; 37 were contacted.

Of these, 8 reported no improvement = 22%
17 reported significant improvement = 46%
12 reported no recurrence of symptoms = 32%

Overall, 22% did not respond
78% did respond.

On the strength of this small sample an hypothesis was proposed: That the underlying cause of chronic headache is a mechanical abnormality of the atlanto-occipital and/or the atlanto-axial joints, which gives rise to a true referred pain within this developmental segment (cf. projected branches of arteries which lie in close anatomical relationship with these joints. This results in vasoconstriction followed by reflex vasodilatation of the cranial blood vessels. In addition, that autonomic nerve irritation in this region gives rise to a miscellany of symptoms other than pain.

A further analysis, in 1975, comprised 268 cases, of whom 163 could be contacted. Of these:

29 were not improved = 17.8%
14 were significantly improved = 8.6%
120 were cured = 73.6%
(These are referred to as 'the sample').

Overall, 82.2% responded to treatment of the neck
17.8% did not.

The proportion of successes to failures, in over 1500 cases over 12 years, remains of the order reported in the two analyses, and further experience suggests an addendum to the hypothesis, i.e.: 'There is a chronic headache which is predictably unresponsive to any treatment of the neck. This might be the pure vascular migraine.' The behaviour of 'pure vascular migraine' is quite different from that of the true cervical headache, but not in the manner suggested by Brain et al.^{3,4,5}

My belief is that the most common cause of chronic headache is not 'migraine' but cervical arthritis, and the fact that this is not generally realized leads to the prevalence of the abandoned headache syndrome.

maybe pretend, that you do.' This deduction was confirmed when she was referred to a psychiatrist. He may have helped her resolve conflicts and tensions, but as tensions do not cause but only precipitate headaches this treatment, at best, could only be palliative. Too often it introduces more drugs, the relaxants.

Now she wore a label. She 'suffers from her nerves'. Her family's ill-concealed suspicion, that her headaches were psychogenic, was confirmed.

This stage marked the patient's loss of confidence in orthodox medicine. She then tried homeopathy, osteopathy, reflexology and acupuncture. The chiropractor was often the only practitioner who seemed to have any effect, but when the pain recurred she was afraid to return to him because of the forceful nature of the manipulation. Having exhausted all these avenues she tried to help herself, as she had been advised, by learning to live with the pain. She tried to do what the psychiatrist had called 'environmental manipulation', meaning that she should alter her circumstances to eliminate factors that could precipitate a headache. But as the headache was continuous and aggravated by the slightest irritation, she was obliged to withdraw from her ordinary life-style. In order to get through the day she resorted to analgesic abuse, which introduced a new disease. It has been shown that 20% of cases of renal failure are due to analgesic nephropathy and that the reason for the excessive drug taking is given as headaches in 75% of these cases.¹

Fortunately, the sensible headache sufferer eventually stops taking any form of analgesia, either because they have become ineffective, or she dislikes the side effects or she is aware of the inherent risks. So it remains for her to face the fact that she has an incurable headache. No more can be done. Everyone is tired of hearing about it. She is abandoned by all to suffer indefinitely in silence. Talk of suicide is not unusual.

Happily, the most dramatic feature in this typical history is the prompt way that this condition will respond to gentle mobilization of the cervical articulations. The pain abates, as do all the associated symptoms. The patient stops taking drugs, shrugs off her neuroses and resumes her responsibilities together with her joy of living. All the hitherto suspected causes of the headache remain, but they no longer give rise to headaches. Her 'incurable' condition has been brought under control by the correct treatment to the cervical spine and thus has been retrospectively diagnosed as a cervical headache.

This narrative is not fictitious and the condition it describes is not rare. In my practice we have seen and treated more than 1500 in 12 years.

The figures that follow are taken from two analyses of cervical headaches whose cervical origin was proved in this

How does it come about that the majority of chronic headaches have not been helped by the medical establishment? The answer may be twofold: (a) although the syndrome will be familiar to every medical practitioner, few recognize its origin. This is because the advanced cervical headache syndrome has not been adequately or reliably documented; (b) when correctly diagnosed, it is incorrectly treated. The treatment recommended in the literature, also that employed by most physiotherapists, produces indifferent results because it is based on outdated concepts.

Why diagnosis fails

Of much research in the field of chronic headache, the emphasis is undoubtedly on the vascular migraine. Scant attention is paid to the importance of cervical headache, as is illustrated in a classification of headaches which was published in the Journal of American Medical Association in 1962.⁶

Classification of headaches

1. Vascular headaches of migraine type
 - a. Classic migraine
 - b. Common migraine
 - c. Cluster headache
 - d. Hemiplegic and ophthalmoplegic migraine
 - e. Lower half headache
 2. Muscle contraction headache
 3. Combined headache. Vascular and muscular origin
 4. Headache of nasal vasomotor origin
 5. Headache of delusional, conversion or hypochondriacal states
 6. Non-migrainous vascular headache
 7. Traction headache
 8. Headache due to overt cranial inflammation
 - 9-13. Headache due to disease of ocular, aural, nasal, sinus, dental or other cranial or neck structures
 14. Cranial neuritis
 15. Cranial neuralgia.
- 6-15 are non-recurrent.

In this classification there are two references to a possible cervical source of headache, i.e. under '2. Muscle contraction headache' which I believe to be a fallacious concept,⁷ and '9-13. Headache due to disease of ocular, aural, nasal, sinus, dental or other cranial or neck structures' in which the neck is all but overlooked, and then excluded as a possible cause of chronic headache by the suggestion that 6-15 are non-recurrent. A great deal has been written about vascular migraine and a review of the literature reveals that most authorities agree on the following typical features:

Classic vascular migraine

- Area of pain: unilateral, localized head pain. Unrelated to the neck generally agreed to be extreme throbbing, bursting, boring
- Intensity of pain: generally agreed to be extreme throbbing, bursting, boring
- Characteristics of pain: unilateral, localized head pain. Unrelated to the neck generally agreed to be extreme throbbing, bursting, boring
- Associated symptoms: visual disturbances, ataxia, dysphasia, disorientation, nausea, vomiting, tinnitus, photophobia and others
- Precipitating factors: tension, eyestrain, noise, bright lights, sinusitis and congestion of nasal mucosa and conjunctiva

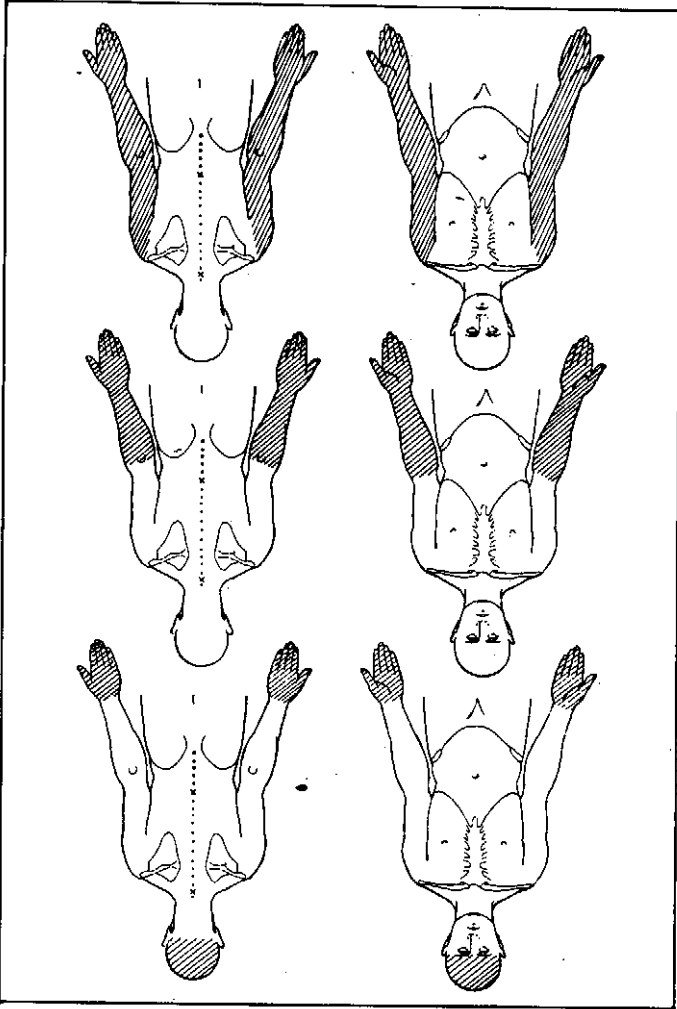
A family history of chronic headache confirms a tentative diagnosis based on these features. Not much seems to have been written about cervical headache and compiling a composite picture from these writings was not easy. There are a great many negative statements which exclude a cervical source in the presence of certain factors. Brain,⁴ whose textbook on clinical neurology has been, for many years, a standard reference for medical students, may have been a source of some confusion in this respect. Because migraine is usually accompanied by a variety of symptoms other than pain, and these symptoms are highlighted in medical writings, they are regarded by many to be reliable diagnostic criteria upon which to base a diagnosis of migraine. The fact that most of these symptoms also accompany a cervical headache is overlooked and even denied.

Cervical headache

Brain (1963)³ suggests, in relation to cervical spondylitis, that 'headache is one of the commonest presenting symptoms of cervical spondylitis'. This was most encouraging, but unfortunately he went on to specify features which, in his view, exclude a diagnosis of cervical origin. These statements are at variance with clinical findings apparent in the sample of 120 proven cervical headaches: 'Area of pain. Brain states that the pain of the cervical headache 'is always occipital' . . . and a headache which spares the occiput is unlikely to be due to spondylitis'.

mid forearm, in 13 it was at the elbow and in 24 it was at the shoulder. These 88 subjects all had symptoms which affected the limbs symmetrically, and mostly with equal severity. The two remaining had symptoms which affected the limbs asymmetrically, i.e. in one limb the upper extent

Fig. 36.1 Common areas of upper limb symptoms Upper diagram shows classical area of head pain^{1,2}



and both upper limbs in the remaining 50. Of the 90 cases seen, one upper limb was affected in 40, all around the affected part. Glove-like indicates that the symptoms are felt equally or both upper limbs (Fig. 36.1).

A glove-like distribution of paraesthesiae (tingling and/or numbness), which may be painful, envelops parts of one or both upper limbs (Fig. 36.1).

Upper limbs

'T4 syndrome' does not mean that T4 is the only level involved, there may be one or more levels affected between T2 and T7,² but the T4 level is nearly always affected. The symptoms of the T4 syndrome affect the upper limbs(s) and the head.

CLINICAL FEATURES

In all cases of the T4 syndrome the hand is affected, by paraesthesiae and similarities between this and other distinct syndromes may make differentiation difficult at times.

A series of 90 patients with T4 syndrome, seen between 1975 and 1983, is presented.

The symptom complex may occur alone or, more commonly in conjunction with other symptoms of pain over the upper thoracic spine, cervical spine, scapulae or the upper limbs.

The cause of the syndrome is unknown, but it may have its referral through the autonomic nervous system, from the upper thoracic area.^{1,2}

The T4 syndrome denotes a symptom complex originating in the upper thoracic spine. This title was first used in 1957 by Maitland and Burnell, of Adelaide. . . . The symptoms are vague and widespread, producing pain and paraesthesiae in the upper limbs, and/or head pain also vague and widespread.

The T4 syndrome

Onset and progression
 The mode of onset of symptoms and their progression was variable. In the majority (57) a cause or predisposing factor was unknown, and waking with the symptoms was the first indication of a problem, or it was supplementary to other cervical and/or upper thoracic pain which already existed. Although the frequency with which the symptoms appear may vary over time, the area and severity of the symptoms usually stays fairly stable. Occasionally the symptoms may be progressive in the area affected and their intensity, i.e. the parasthesia can begin in one hand, and over time ascend the limb. It may then proceed to affect the opposite limb in a like manner. The length of time from when symptoms began until attending for treatment was also variable, (from a few days to 6 years); generally patients sought treatment earlier when symptoms were appearing very frequently or when other associated cervical or thoracic symptoms were present, and many sought treatment primarily for the associated symptoms.

was at the wrist, while in the other limb the upper extent was at the elbow. Occasionally the symptoms in the hand may be different to those in the more proximal parts. For example, numbness in the hand while there is tingling in the forearm.

Head

A dull aching or pressure feeling in an 'all over' distribution (see Fig. 36.1) has been described.^{1,2} The head may also feel 'larger than normal'.

It is by no means invariable that upper limb and head pain occur together in the same patient; it was found in this series that their association occurred in only 32 of the 90 patients seen, and only 14 of these had this all over head pain described above. The other 18 had occipital or frontal head pain, either unilaterally or bilaterally distributed, and it was difficult to say whether this head pain was from the cervical area or from the upper thoracic area.

Occurrence of symptoms

When the symptoms appear, all involved parts are affected simultaneously.

The symptoms were usually intermittent (88) but occasionally constant (2); they occurred either, at night waking the patient from sleep in the early hours of the morning (63), or when they woke at the usual time (27). Symptoms may occur every day or a few times per week, or less frequently. Patients commonly state that they were lying supine when they woke with the symptoms, others were affected when lying on their sides. Relief was achieved by changing position in the bed or by standing up; shaking or rubbing the affected parts seemed to help. The symptoms took from a few minutes to half an hour to abate. Other activities, such as driving a car or reading a newspaper, occasionally brought on the symptoms (3).

Area of symptoms

Because the patient is commonly woken from sleep at night it may be difficult for them to be sure of the precise area affected and it may be necessary to have them take particular note of this aspect when it next occurs and report at the next treatment session.

Sex distribution

Females 71/90 = 79%
 Males 19/90 = 21%

Ratio of Females to Males = 3.7:1

Predisposing factors

Unaccustomed lifting, stretching, pushing or exercises were blamed for the onset of symptoms in 14, and trauma in the form of a motor vehicle accident or a fall preceded the onset of symptoms in 19. 59 patients knew of no cause or predisposing factor. It is possible that a relaxed posture, with a forward poking chin, accentuated thoracic kyphosis and protracted shoulder girdle, may predispose the patient to this syndrome. This posture places a prolonged stretch on the upper and mid thoracic structures when in the erect position. When the patient lies down, especially supine, the kyphosis and stretch on the upper and mid thoracic areas are reduced, and the production of symptoms, in the susceptible patient, may be a 'release phenomenon'.

Loeb³ has shown that there is an age related change of the angle of incline of the upper thoracic spine, which is greater in females, and the greatest change occurs over the age of 60 years (see Table 36.2). In the 'less than 40 years' group the female upper thoracic incline is 4°-5° straighter

Table 36.1 Age distribution of patients in the T4 syndrome

Age in years	Incidence
11-20	2 (2.2%)
21-30	19 (21.1%)
31-40	30 (33.3%)
41-50	28 (31.1%)
51-60	6 (6.7%)
61-70	5 (5.6%)
90	5 (5.6%)