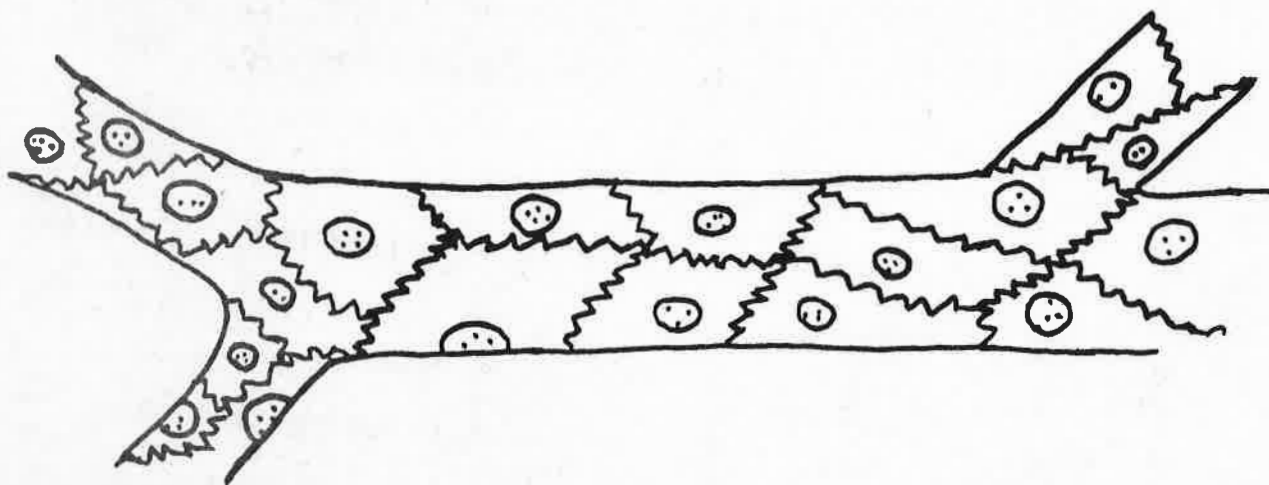


SECTION OF A CAPILLARY WALL



The capillary wall is composed of a single layer of endothelial cells and is about the most tenuous structure conceivable. It does not exceed half a micron in thickness.

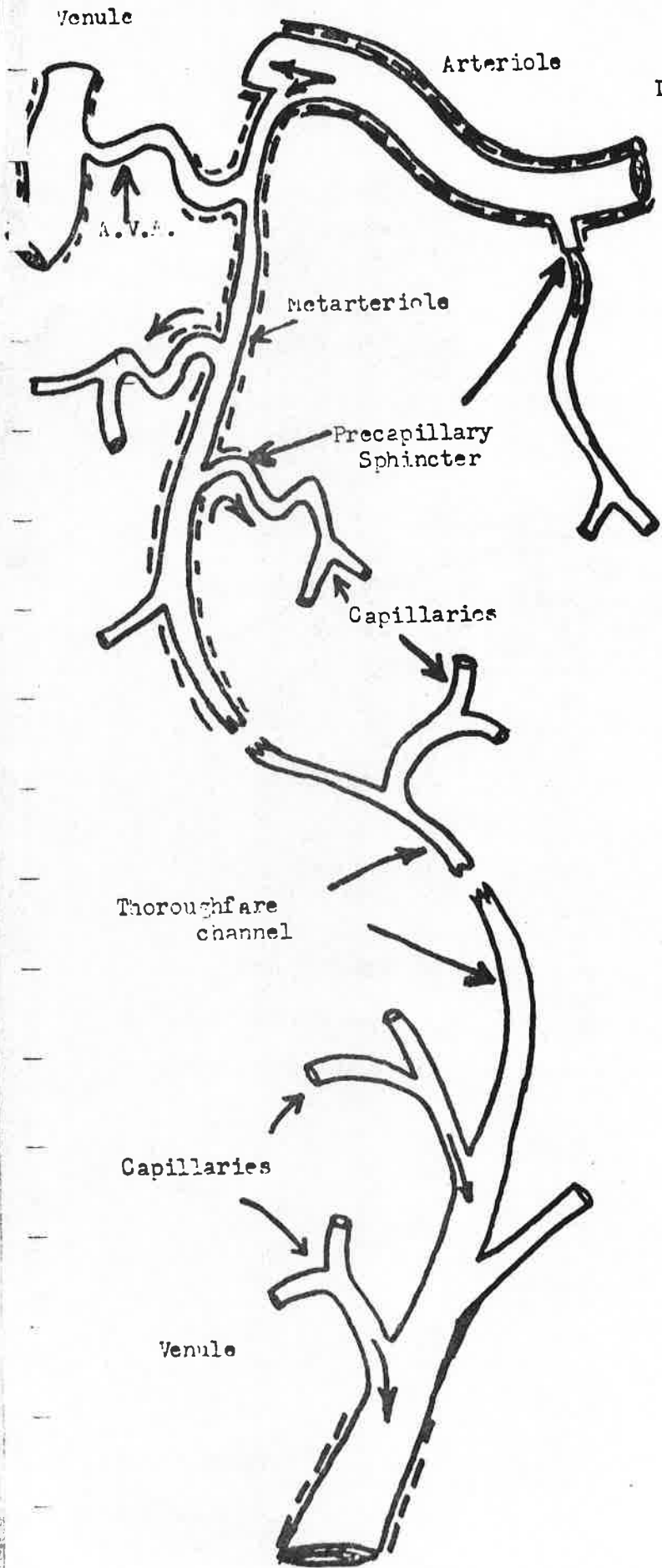
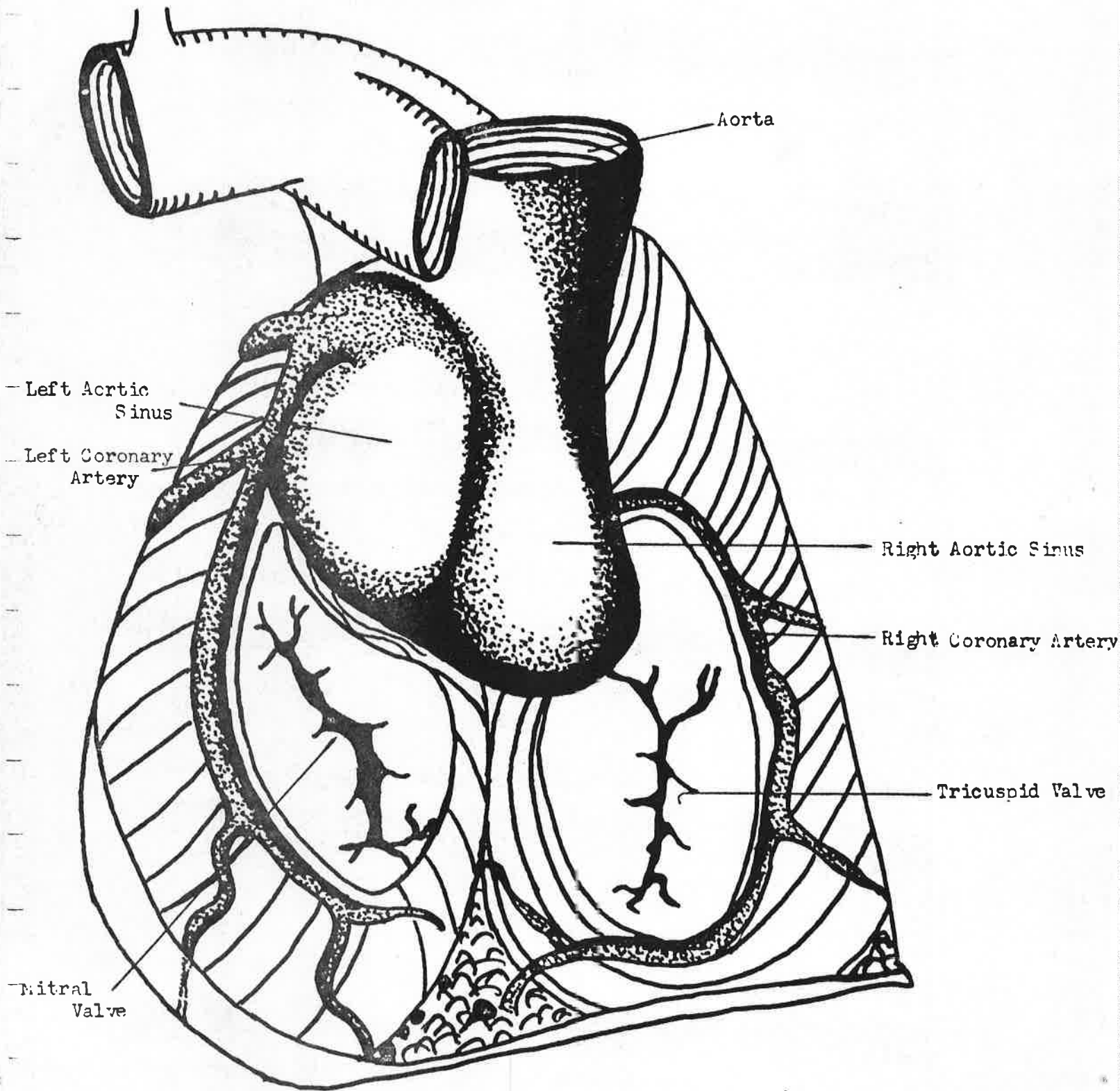


DIAGRAM of FUNCTIONAL UNIT OF THE CAPILLARY BED

Blood flows generally from the arterioles directly into a metarteriole, and then into capillaries. The metarterioles lead directly into channels which are main thoroughfares from the capillary bed to the venules. The true capillaries concerned with interchange between blood and tissues are inter-anastomosing side branches of the main channels through the bed. At the ostia of each capillary is a small pre capillary sphincter of smooth muscle which is controlled by nerves presumably from the sympathetic nervous system, in the same manner that these nerves control the arterioles and metarterioles.

AORTIC SINUSES and CORONARY ARTERIES



DIAGNOSTIC PULSES

Normal Pulse. 74 Beats per Minute.



Full, Strong, Regular Pulse.

Hyper-thyroid Pulse (Shot Pulse). 120 Beats per Minute.



Fast, Small, Hard Pulse. HOT.

Hypo-thyroid Pulse (Oval Pulse). 120 Beats per Minute.



Fast, Small, Soft Pulse. Oftimes with a Purr. COLD.

Hypo-adrenia Pulse (Wiener Pulse). 120 Beats per Minute.



Fast, Small, Weak, Long Pulse.

Hepatic-Toxic Pulse (Pressure Pulse) 120 Beats per Minute.



Fast, Full, Pounding Pulse.

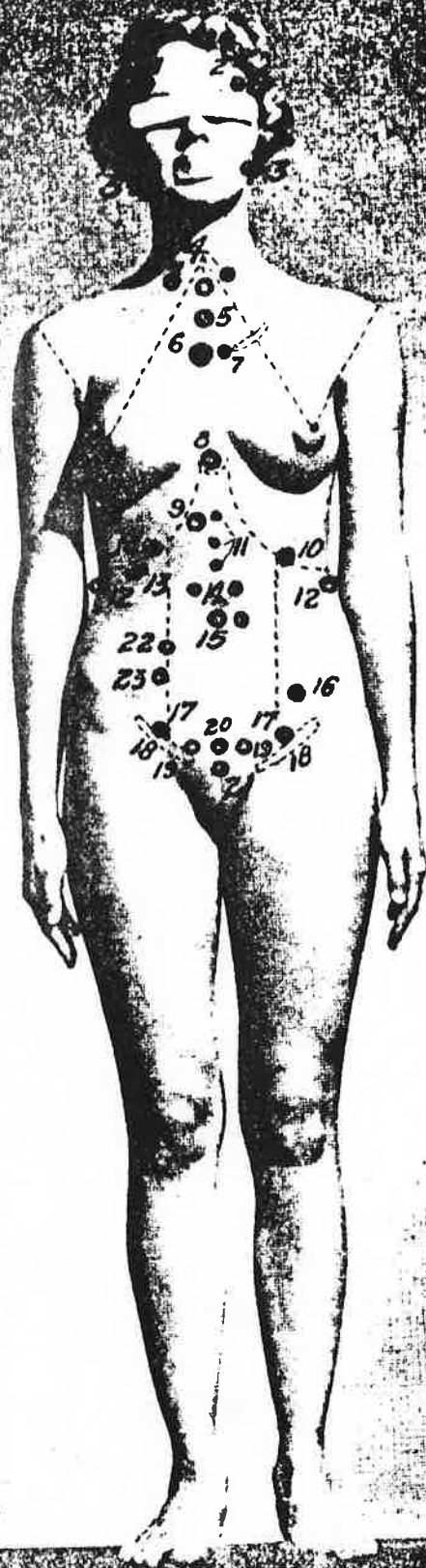
Hepatic-Pituitary Pulse (Low Adrenal) 120 Beats per Minute, Plus.



Fast, Irregular, Two Full, followed by Two Small, rapid beats, producing a jerking of the Heart.

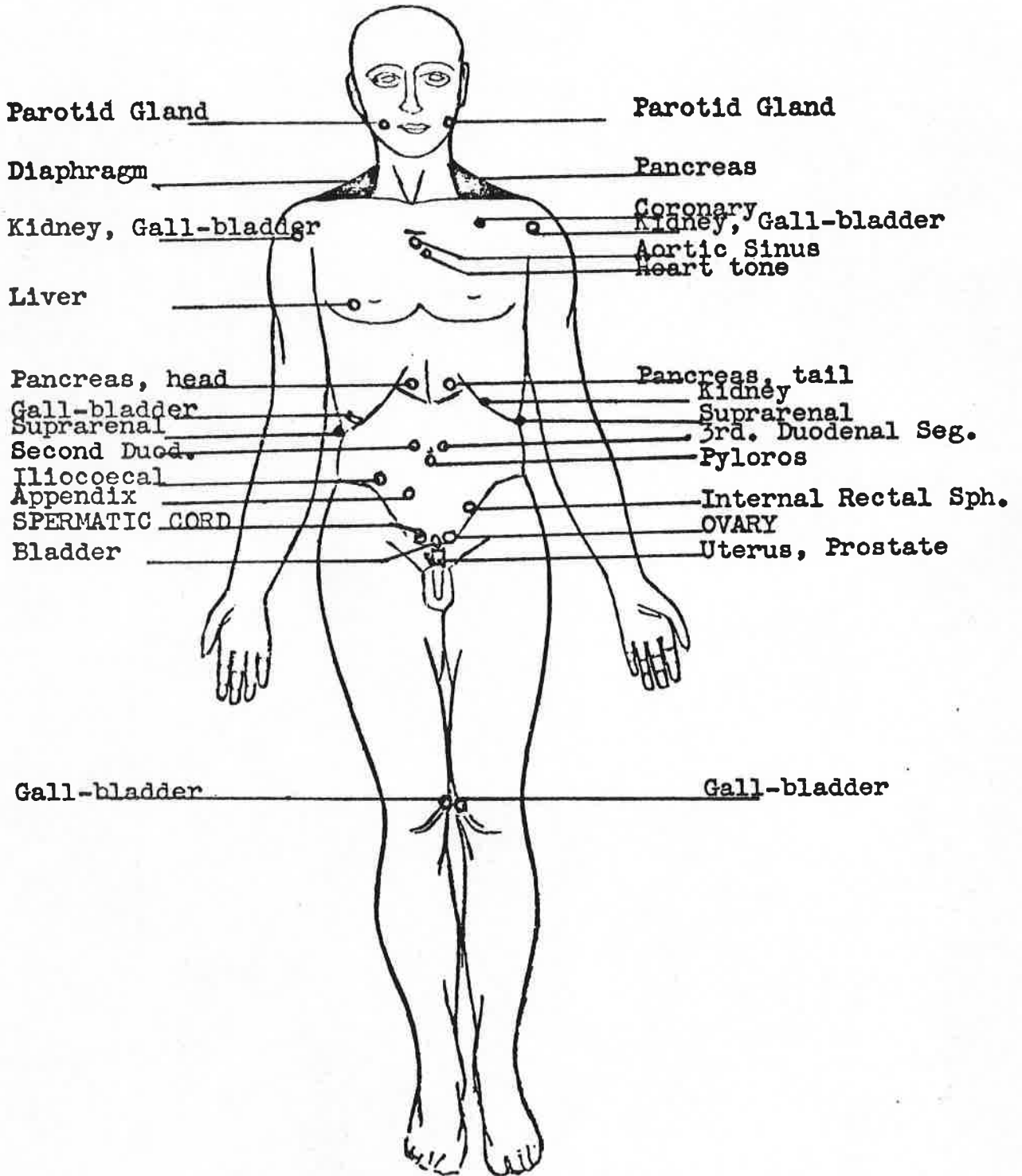
Dr. T. J. Bennett.





- 1-Anterior Pituitary
- 2-Posterior Pituitary
- 3-Parotid Gland
- 4-Thyroid Gland
- 5-Bronchial Gough
- 6-Aortic Sinus
- 7-Heart Tone
- 8-Cardiac Sphincter
- 9-Pancreas
- 10-Kidney
- 11-M^c Kenzie Reflex
- 12-Suprarenal
- 13-Gall Bladder
- 14-Duodenum(2nd, 3rd, 4th)
- 15-Pylorus
- 16-Int. Rectal Sph.
- 17-Fem Lymphatics
- 18-Poupart's Lig.
- 19-Ovario (Teste)
- 20-Bladder
- 21-Uterus(Prostate)
- 22-Ileocecal
- 23-Appendix

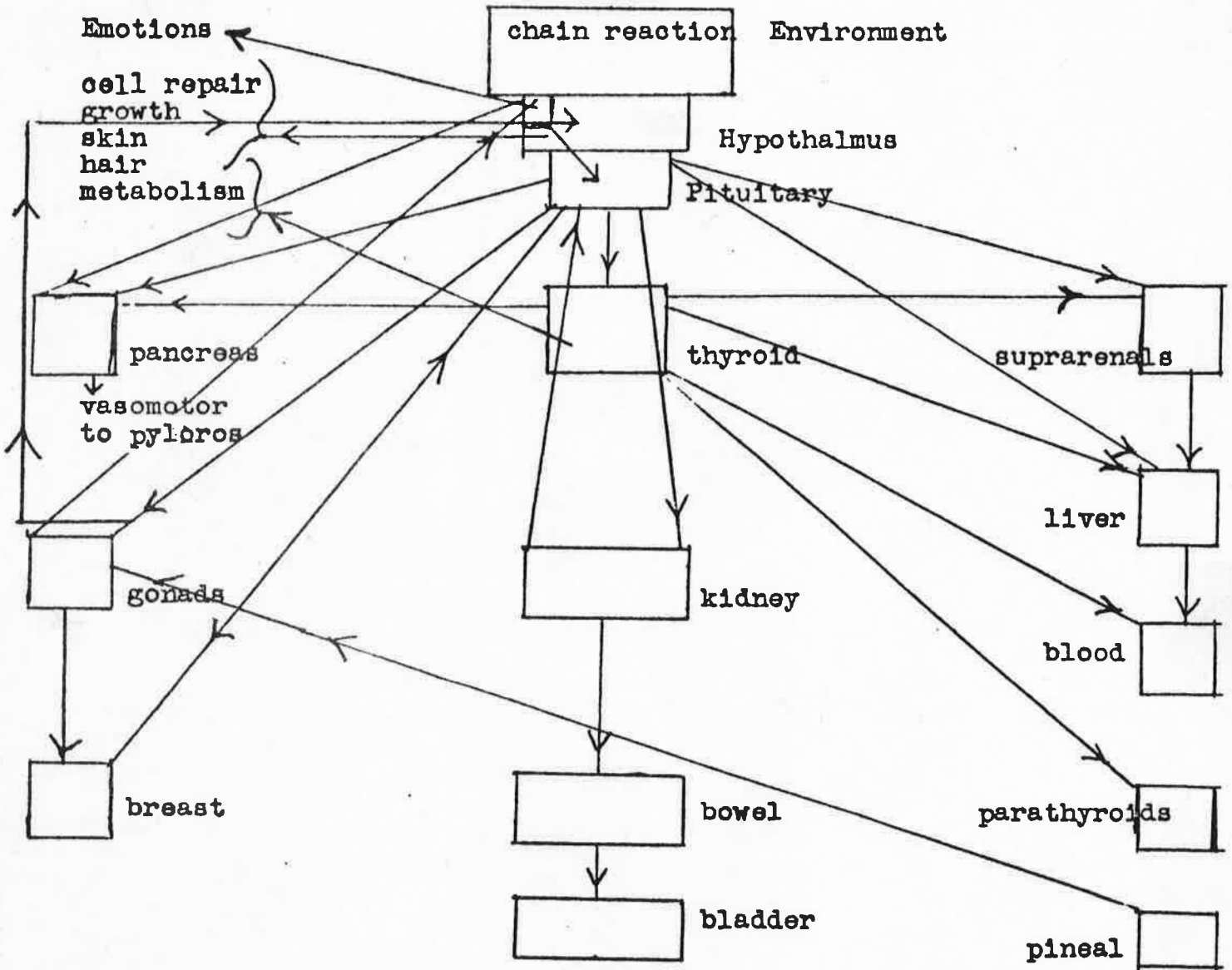
**A BASIS FOR THE CORRECTION OF ABNORMAL PHYSIOLOGY
DIAGNOSTIC REFLEXES**



NEUROLOGICAL RESEARCH FOUNDATION, INC.

SAN FRANCISCO, CALIFORNIA

CHEMICAL LEVEL OF BALANCE



ARROWS POINT DIRECTION OF INFLUENCE

T. J. BENNETT 1956

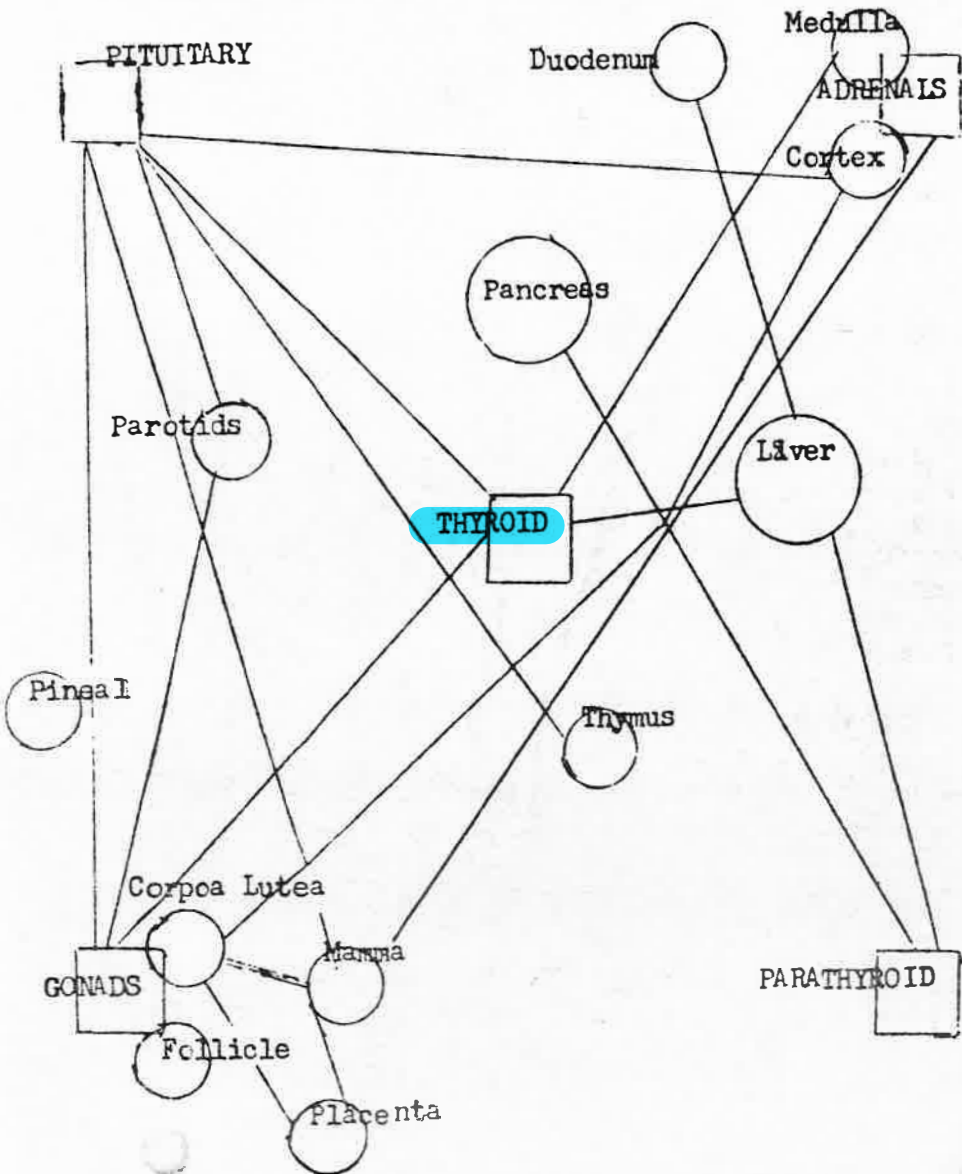
NEUROVASCULAR DYNAMICS

ENDOCRINE RELATIONSHIPS

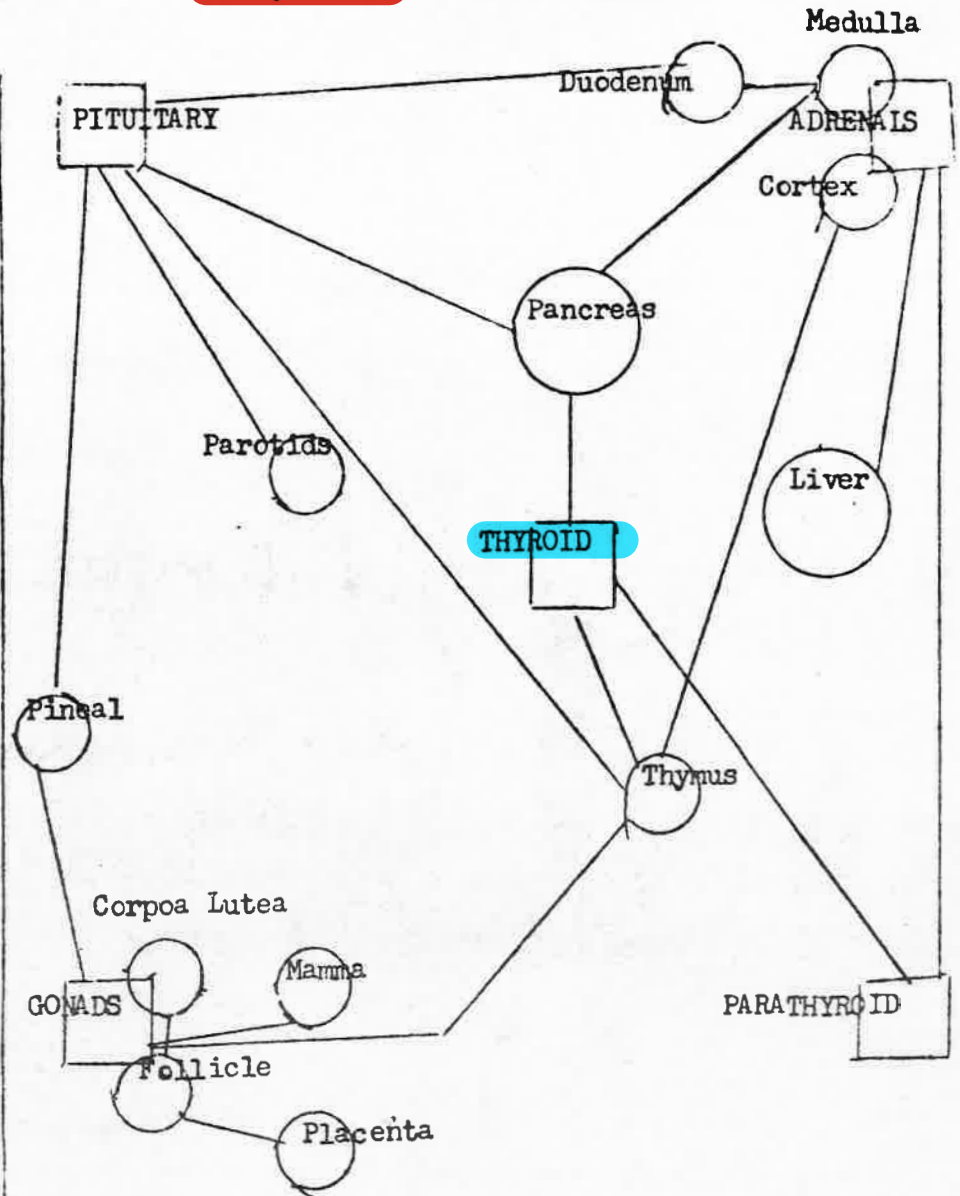
COPYRIGHT 1963 © Ralph J. Martin D.C.

All rights reserved

Cooperative Glands & Organs

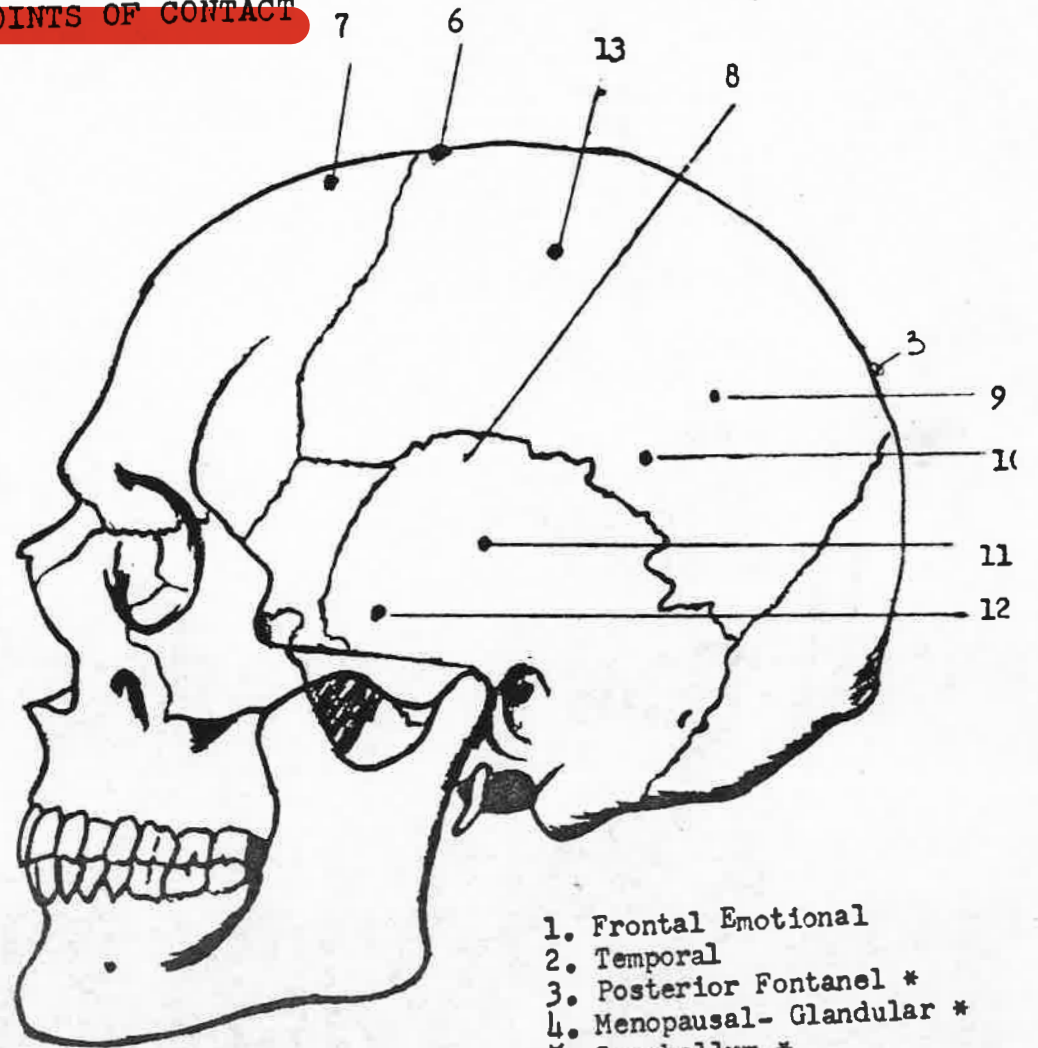
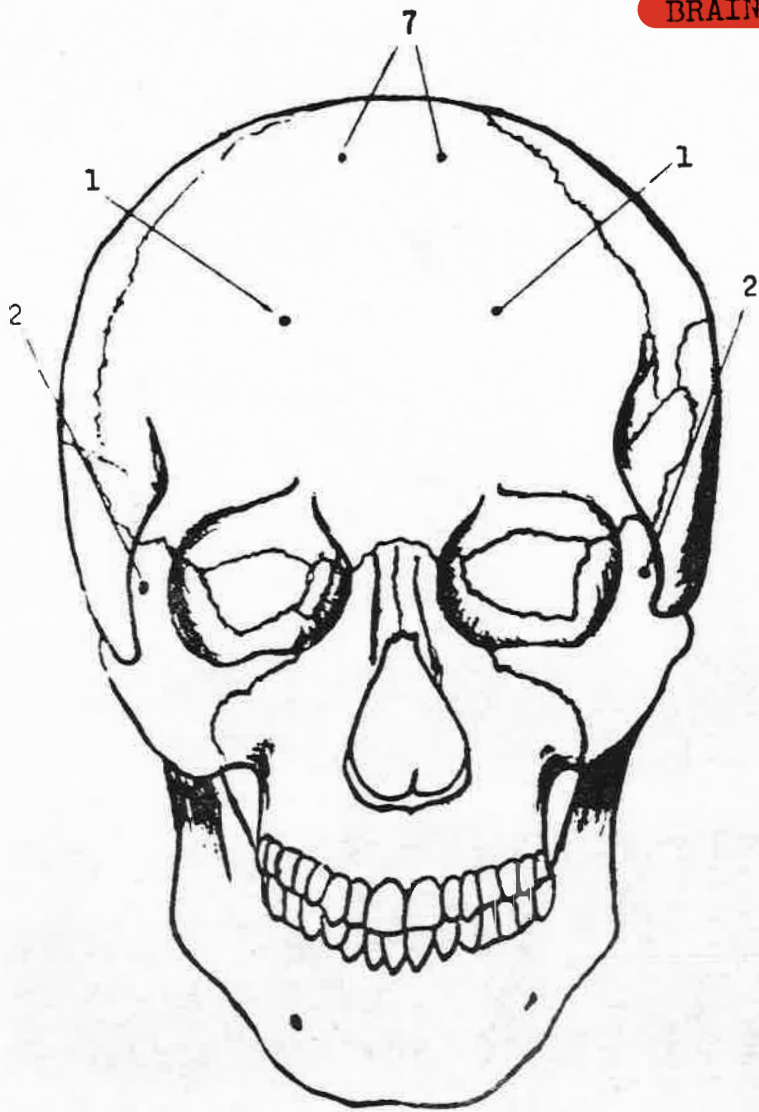


Antagonistic Glands & Organs



NEUROVASCULAR DYNAMICS

BRAIN REFLEX POINTS OF CONTACT



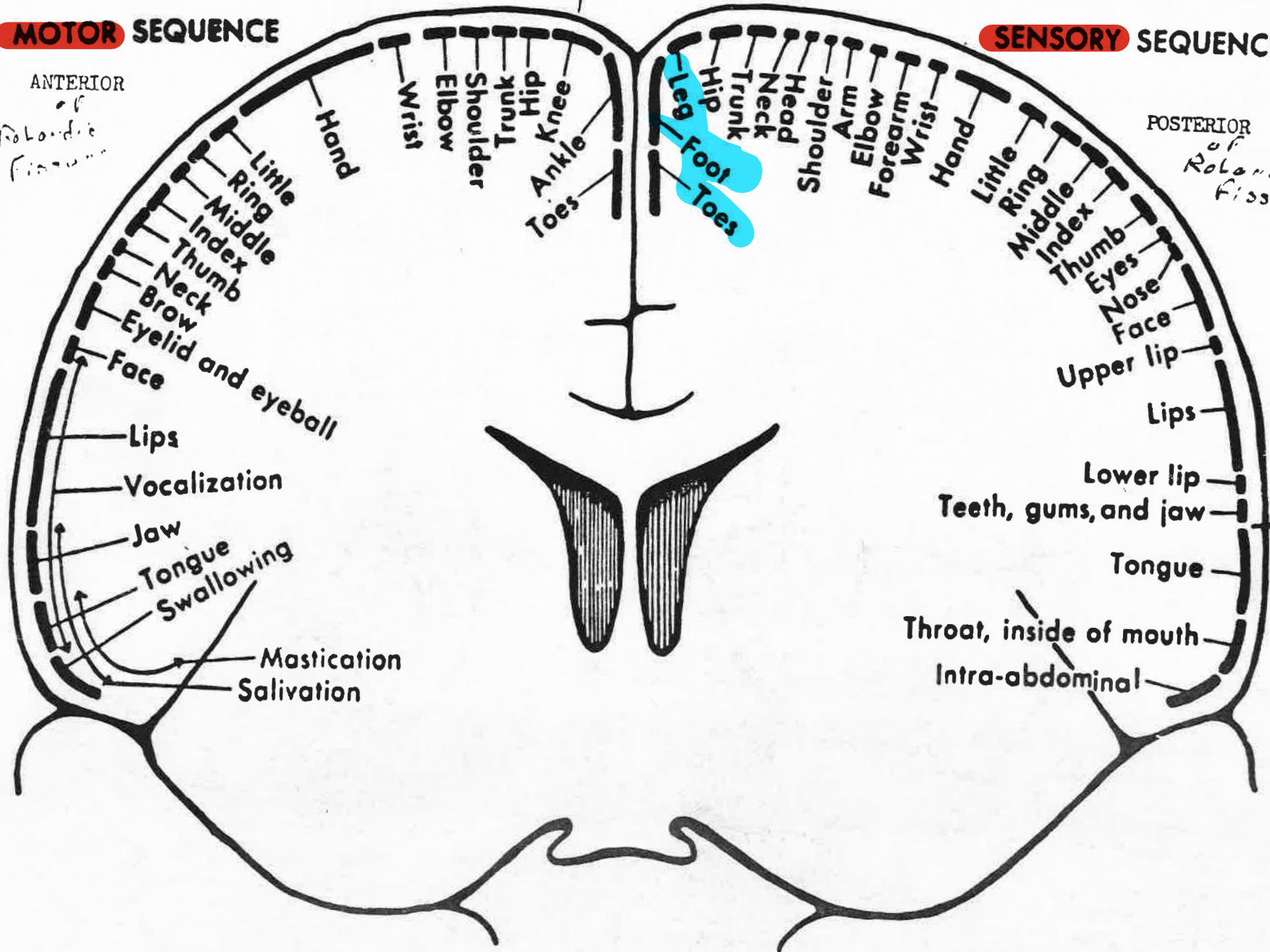
1. Frontal Emotional
 2. Temporal
 3. Posterior Fontanel *
 4. Menopausal- Glandular *
 5. Cerebellum *
 6. Anterior Fontanel
 7. Frontal Eye Fields
 8. Fissure of Rolendo
 9. Parietal
 10. Vaginal
 11. Midsylvian
 12. Temporal Emotional
 13. Kidney
- * Not shown on this chart

MOTOR SEQUENCE

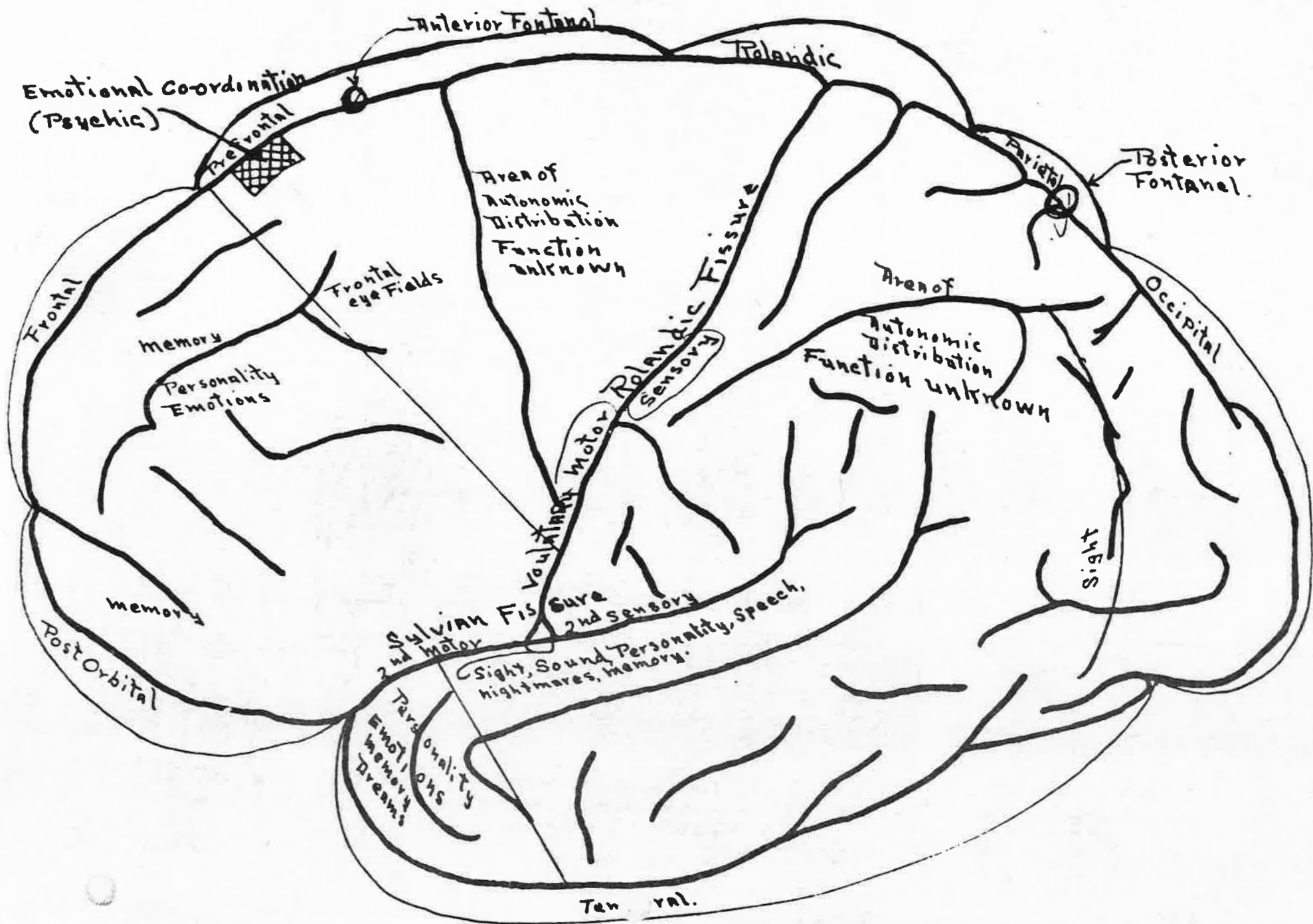
SENSORY SEQUENCE

ANTERIOR
of
Rolandic
Fissure

POSTERIOR
of
Rolandic
Fissure

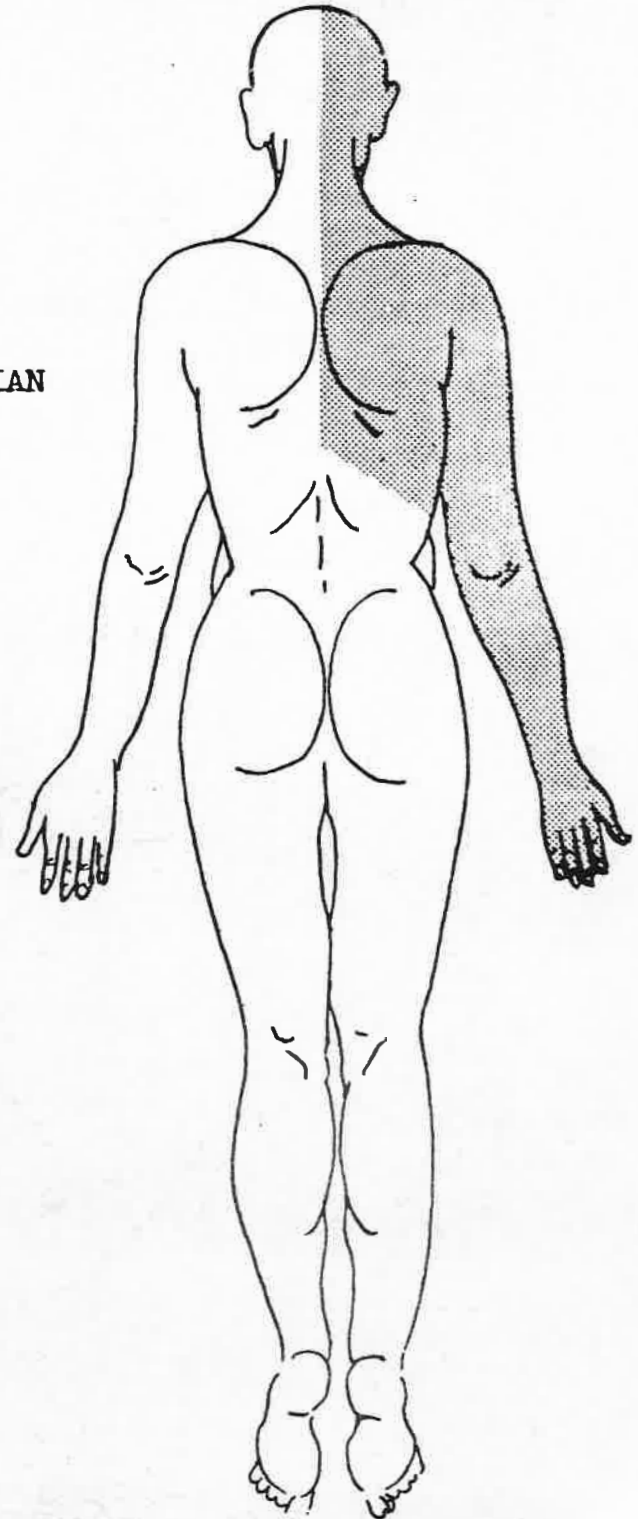
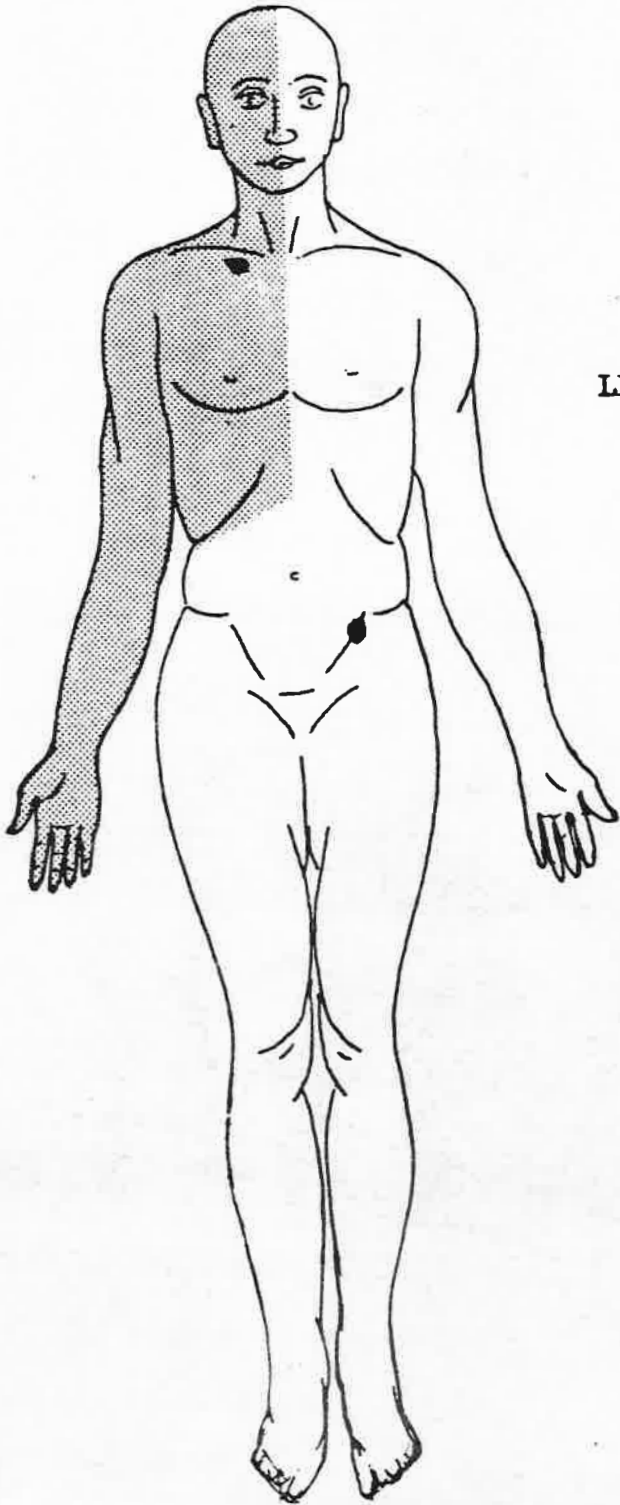


NEUROVASCULAR DYNAMICS



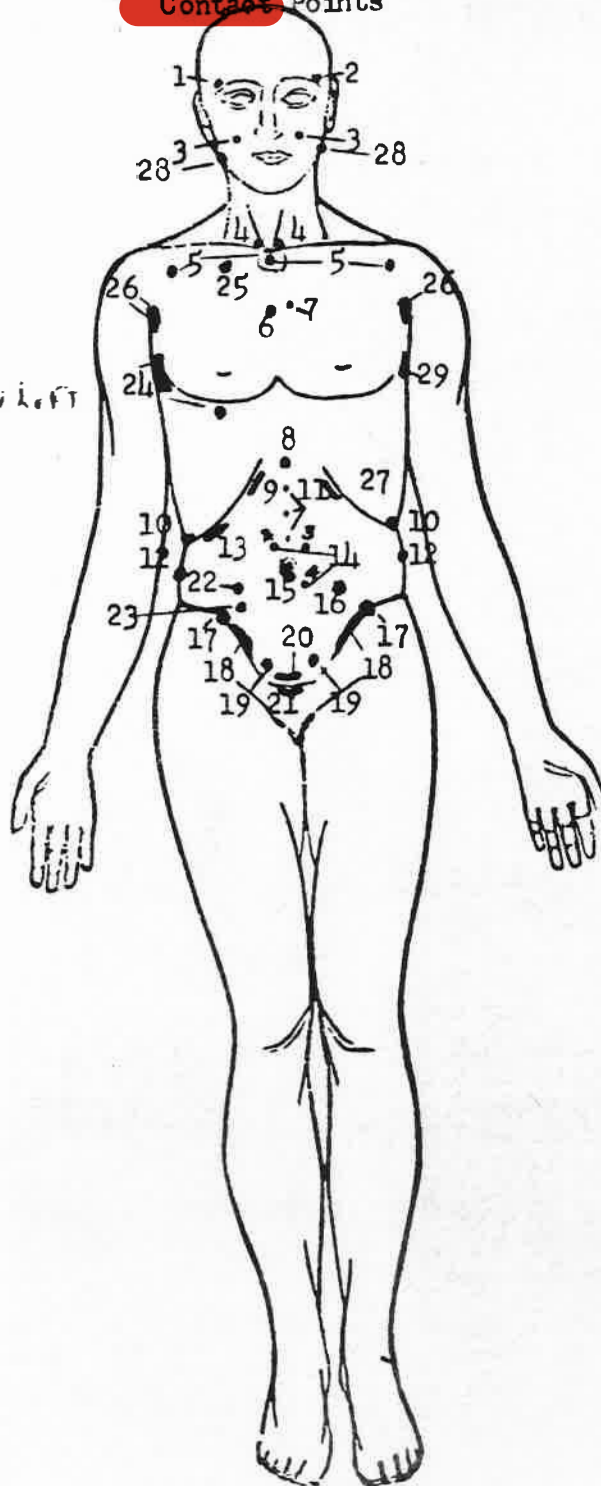
DR. RALPH J. MARTIN
CHIROPRACTOR
BOX 1052 FOOTHILL ROAD
LUCERNE VALLEY, CALIFORNIA
92356

LEFT FEMORAL AND RIGHT SUBCLAVIAN
LYMPHATIC CONTROL POINTS



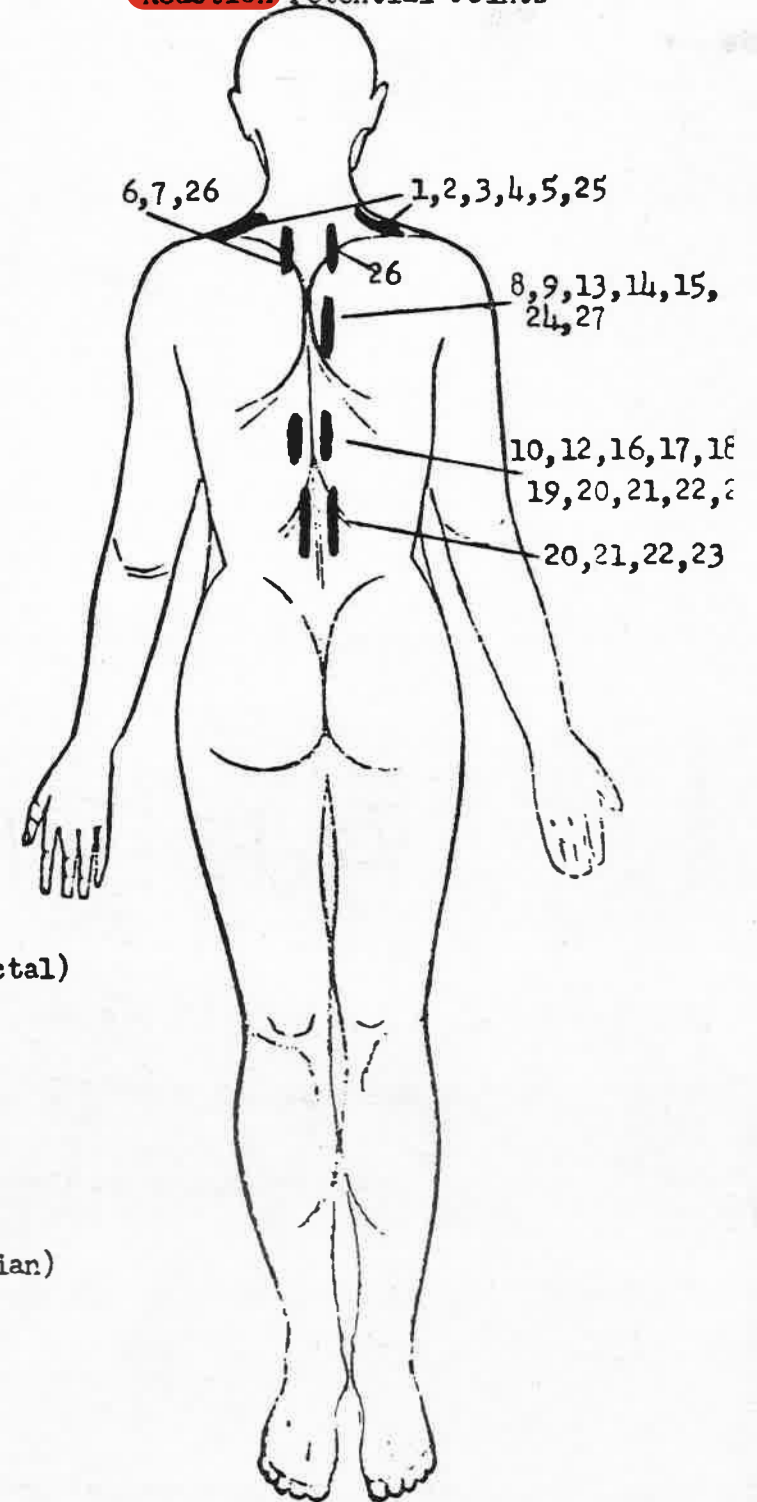
NEUROVASCULAR DYNAMICS

Contact Points



DR. RALPH J. MARTIN
 CHIROPRACTOR
 BOX 1052 FOOTHILL ROAD
 LUCERNE VALLEY, CALIFORNIA
 92356

Reaction Potential Points



NEUROVASCULAR DYNAMICS

Visceral Contact Points

1. Anterior Pituitary
2. Posterior Pituitary
3. Parotid Gland
4. Thyroid Gland
5. Bronchii - ⑤ Thymus
6. Aortic Sinus
7. Heart Tone
8. Cardiac Sphincter
9. Pancreas (Head)
10. Kidney
11. McKenzie Reflexes
12. Suprenals
13. Gall Bladder
14. Duodenum (2,3 & 4)
15. Pylorus
16. Houston's Valves (Int.Rectal)
17. Femoral Lymphatics
18. Poupart's Ligament
19. Ovaries and Testes
20. Urinary Bladder
21. Uterus
22. Ileocecal Valve
23. Appendix
24. Liver
25. Lymphatic (Right Subclavian)
26. Bronchii and Lungs
27. Pancreas (Tail)
28. Carotid Sinus
29. Spleen